

# Systematic review of the incidence, presentation and management of gastroduodenal artery pseudoaneurysm after pancreatic resection

B. Brodie<sup>1</sup> and H. M. Kocher<sup>2,3</sup> 

<sup>1</sup>Barts and the London School of Medicine and Dentistry, <sup>2</sup>Centre for Tumour Biology, Barts Cancer Institute, Queen Mary University of London, and

<sup>3</sup>Barts and the London Hepato-Pancreato-Biliary Centre, The Royal London Hospital, Barts Health NHS Trust, Whitechapel, London, UK

Correspondence to: Professor H. M. Kocher, Centre for Tumour Biology, Barts Cancer Institute, Queen Mary University of London, Charterhouse Square, London EC1M 6BQ, UK (e-mail: h.kocher@qmul.ac.uk)

**Background:** Gastroduodenal artery (GDA) pseudoaneurysm is a serious complication following pancreatic resection, associated with high morbidity and mortality rates. This review aimed to report the incidence of GDA pseudoaneurysm after pancreatic surgery, and describe clinical presentation and management.

**Methods:** MEDLINE and Embase were searched systematically for clinical studies evaluating postoperative GDA pseudoaneurysm. Incidence was calculated by dividing total number of GDA pseudoaneurysms by the total number of pancreatic operations. Additional qualitative data related to GDA pseudoaneurysm presentation and management following pancreatic resection were extracted and reviewed from individual reports.

**Results:** Nine studies were selected for systematic review involving 4227 pancreatic operations with 55 GDA pseudoaneurysms, with a reported incidence of 1.3 (range 0.2–8.3) per cent. Additional data were extracted from 39 individual examples of GDA pseudoaneurysm from 14 studies. The median time for haemorrhage after surgery was at 15 (range 4–210) days. A preceding complication in the postoperative period was documented in four of 21 patients (67 per cent), and sentinel bleeding was observed in 14 of 20 patients (70 per cent). Postoperative complications after pseudoaneurysm management occurred in two-thirds of the patients (14 of 21). The overall survival rate was 85 per cent (33 of 39).

**Conclusion:** GDA pseudoaneurysm is a rare yet serious cause of haemorrhage after pancreatic surgery, with high mortality. The majority of the patients had a preceding complication. Sentinel bleeding was an important clinical indicator.

#### Funding information

No funding

Paper accepted 10 June 2019

Published online 30 September 2019 in Wiley Online Library (www.bjsopen.com). DOI: 10.1002/bjs.5.50210

## Introduction

Mortality from pancreatic resection has fallen significantly over the past few decades, especially in experienced centres<sup>1–3</sup>. Morbidity, including delayed gastric emptying, anastomotic leak and pancreatic fistula, remains high, affecting around 20–40 per cent of patients<sup>4–6</sup>. Postoperative haemorrhage is less common, but is a life-threatening event with an estimated mortality rate of 20–50 per cent<sup>7,8</sup>. Early-onset haemorrhage is rare, and generally occurs within 24 h, usually due to technical failures. Delayed haemorrhage occurring days or weeks

after surgery occurs for a variety of reasons, but one cause of massive haemorrhage is from the formation of visceral arterial pseudoaneurysms. Although several arteries have been shown to be vulnerable to pseudoaneurysm formation, observational studies indicate that pseudoaneurysms of the gastroduodenal artery (GDA) are the most common<sup>9–11</sup>.

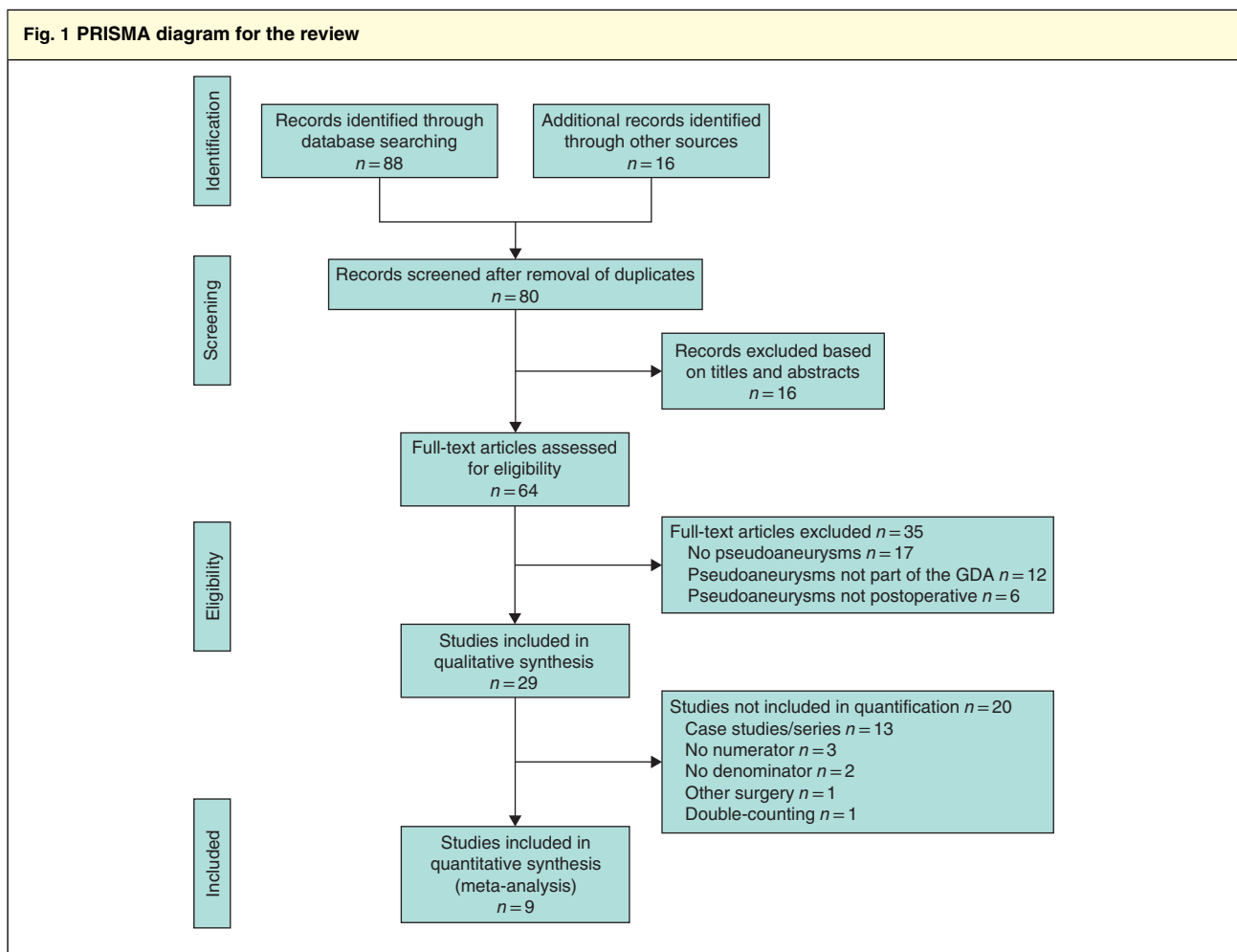
The aim of this systematic review was to synthesize existing evidence regarding the incidence, clinical presentation and management of GDA pseudoaneurysms after pancreatic surgery.

## Methods

Studies evaluating GDA pseudoaneurysm formation after pancreatic surgery were identified by means of database searches of MEDLINE and Embase. In Embase the terms used were: 'false-aneurysm' AND 'gastroduodenal artery' AND 'pancreaticoduodenectomy' OR 'pancreatectomy' OR 'distal pancreatectomy' OR 'pylorus preserving pancreaticoduodenectomy' OR 'pancreas surgery'. In MEDLINE the terms used were: 'false aneurysm' OR 'pseudoaneurysm' AND 'gastroduodenal artery' AND 'pancreaticoduodenectomy' OR 'pancreas surgery' OR 'pancreatectomy' OR 'distal pancreatectomy' OR 'pylorus preserving pancreaticoduodenectomy'.

A manual reference search was also performed to identify additional observational studies. No language restrictions were applied. Inclusion criteria were: manuscript published in a peer-reviewed journal until 2017, investigating adult

patients aged over 18 years, undergoing pancreatic surgery for any indication, developing GDA pseudoaneurysm, and reporting clinical outcomes of interest. The authors independently reviewed all relevant titles and abstracts, and all disagreements were resolved by consensus. Observational studies that reported both the number of GDA pseudoaneurysms and the total number of pancreatic operations performed were used for quantitative analysis of incidence. Qualitative information also relevant to the clinical presentation and management of GDA pseudoaneurysms was extracted from individual cases and collated. Data extracted included index surgery, sentinel bleeding defined as haemorrhage that occurred in the gastrointestinal tract (intraluminal) or intra-abdominally (through a surgical drain) between 6 h and 10 days before a massive haemorrhage in the postoperative setting, day of postoperative bleeding, diagnostic method, management,



GDA, gastroduodenal artery.

**Table 1 Studies included for determination of incidence**

Reference	Country	Study interval	Surgical procedures	Total no. of operations	Total no. of GDA pseudoaneurysms	Incidence (%)
Adam <i>et al.</i> <sup>11</sup>	Turkey	January 1995 to January 2013	PD	342	7	2.0
Suzuki <i>et al.</i> <sup>33</sup>	Japan	January 2012 to July 2016	PD	88	5	6
Jeong <i>et al.</i> <sup>31</sup>	South Korea	October 1994 to December 2012	PD	1905	18	0.9
Yada <i>et al.</i> <sup>32</sup>	Japan	1982–2010	PD + PPPD	361	1	0.3
Loveček <i>et al.</i> <sup>34</sup>	Czech Republic	2006–2015	PD	449	1	0.2
Fujii <i>et al.</i> <sup>10</sup>	Japan	January 1993 to December 2005	PD + PPPD + DP + SR + HPD + TP	351	3	0.9
Rajaratnam <i>et al.</i> <sup>35</sup>	India	January 1998 to December 2007	PD	458	2	0.4
Hur <i>et al.</i> <sup>36</sup>	South Korea	March 2003 to March 2008	PD	192	16	8.3
Sato <i>et al.</i> <sup>37</sup>	Japan	January 1992 to December 1997	PD	81	2	2
Total				4227	55	1.3

GDA, gastroduodenal artery; PD, pancreateoduodenectomy; PPPD, pylorus-preserving pancreateoduodenectomy; DP, distal pancreatectomy; SR, segmental resection; HPD, pancreateoduodenectomy plus hepatic resection; TP, total pancreatectomy.

**Table 2 Data extracted for 39 patients with gastroduodenal artery pseudoaneurysm**

Reference	Patient no.	Age (years)	Sex	Surgery	Complication	Sentinel bleed	POD of bleed	Diagnostic method	Management	Survival
Adam <i>et al.</i> <sup>11</sup>	1	43	M	PD	None	Yes	45	Angiography	Selective embolization	Yes
	2	68	F	PD	Abscess	Yes	10	Angiography	Selective embolization	Yes
	3	59	M	PD	Abscess	Yes	4	Angiography	TAE of CHA	Yes
	4	41	M	PD	Abscess	Yes	23	Angiography	TAE of CHA	Yes
	5	63	M	PD	Abscess	Yes	14	Angiography	Selective embolization	No
	6	72	F	PD	Abscess	Yes	25	Angiography	Selective embolization	Yes
	7	51	M	PD	None	Yes	7	Angiography	TAE of CHA	Yes
Fujii <i>et al.</i> <sup>10</sup>	1	–	–	HPD	Pancreatic leak	–	10	Angiography	TAE of CHA	Yes
	2	–	–	PD	Pancreatic fistula	–	11	Angiography	Relaparotomy	Yes
	3	–	–	HPD	Pancreatic leak	–	7	Angiography	Relaparotomy	No
Rajaratnam <i>et al.</i> <sup>35</sup>	1	52	M	PD	Pancreatic fistula	No	17	Angiography	Relaparotomy	Yes
	2	67	M	PD	Intra-abdominal abscess	Yes	17	Angiography	Relaparotomy	No
Hur <i>et al.</i> <sup>36</sup>	1	–	–	PPPD	–	–	8	–	TAE of CHA	No
	2	–	–	PPPD	–	–	6	–	TAE of CHA	Yes
	3	–	–	PD	–	–	23	–	Selective embolization	Yes
	4	–	–	LPD	–	–	15	–	TAE of CHA	Yes
	5	–	–	LPD	–	–	7	–	Selective embolization	Yes
	6	–	–	PPPD	–	–	12	–	TAE of CHA	Yes
	7	–	–	PPPD	–	–	11	–	Selective embolization	No
	8	–	–	PPPD	–	–	7	–	TAE of CHA	Yes
	9	–	–	PPPD	–	–	8	–	TAE of CHA	Yes
	10	–	–	PPPD	–	–	19	–	TAE of CHA	Yes
	11	–	–	PPPD	–	–	7	–	TAE of CHA	Yes
	12	–	–	PPPD	–	–	19	–	TAE of CHA	Yes
	13	–	–	PPPD	–	–	8	–	TAE of CHA	Yes
	14	–	–	PPPD	–	–	14	–	TAE of CHA	Yes
	15	–	–	HPD	–	–	9	–	TAE of CHA	Yes
	16	–	–	PPPD	–	–	13	–	TAE of CHA	Yes

Table 2 Continued											
Reference	Patient no.	Age (years)	Sex	Surgery	Complication	Sentinel bleed	POD of bleed	Diagnostic method	Management	Survival	
Miyazawa <i>et al.</i> <sup>13</sup>	1	71	M	PD	Postoperative bleed	No	180	Contrast CT	Stenting	Yes	
Loveček <i>et al.</i> <sup>14</sup>	1	58	M	PD	None	Yes	18	Angiography	Stenting	Yes	
Mazza <i>et al.</i> <sup>16</sup>	1	61	M	MSR	None	No	210	Contrast CT	Selective embolization	Yes	
Huang <i>et al.</i> <sup>17</sup>	1	72	M	PD	–	Yes	17	–	Selective embolization	Yes	
	2	65	F	Duodenum-preserving pancreatic resection	–	Yes	30	–	Selective embolization	No	
Noun <i>et al.</i> <sup>18</sup>	1	58	M	PD	Pancreatic fistula	Yes	19	Angiography	Selective embolization	Yes	
Orsenigo <i>et al.</i> <sup>21</sup>	1	38	M	SPK	AV fistula	No	15	MR angiography	Selective embolization	Yes	
Sugimoto <i>et al.</i> <sup>22</sup>	1	62	M	PD	None	No	120	Angiography	TAE of CHA	Yes	
Born <i>et al.</i> <sup>23</sup>	1	42	M	Lateral pancreaticojejunostomy	None	Yes	21	Angiography	TAE of CHA	Yes	
Teramoto <i>et al.</i> <sup>24</sup>	1	70	M	PD	Pancreatic leak	No	34	Angiography	Selective embolization	Yes	
Okuno <i>et al.</i> <sup>30</sup>	1	46	F	PD	None	Yes	62	Angiography	Selective embolization	Yes	
Overall	39	60*	16 M, 4 F		14 of 21	14 of 20	15 (4–210)*			33 of 39	

\*Median (range) value. POD, postoperative day; PD, pancreatoduodenectomy; TAE, transarterial embolization; CHA, common hepatic artery; HPD, pancreatectomy plus hepatic resection; PPPD, pylorus-preserving pancreatoduodenectomy; LPD, laparoscopic pancreatoduodenectomy; MSR, middle segment resection; SPK, simultaneous pancreas–kidney transplant.

other postoperative complications and mortality. GDA pseudoaneurysms were confirmed either radiologically or during surgery in all studies.

## Results

A PRISMA flow diagram is shown in *Fig. 1*. Some 88 studies were initially identified, 80 were screened, and 29 fulfilled the inclusion criteria. Of these, 13 studies<sup>12–24</sup> were not included in the quantification as they were case series dealing exclusively with GDA pseudoaneurysms.

Five further studies were excluded as they did not provide the rate of GDA pseudoaneurysm in the postoperative period<sup>125–27</sup>, or the total number of pancreatic operations performed<sup>128,29</sup>. One study<sup>30</sup> was excluded because it also included procedures not involving the pancreas (hepatic resection and gastrojejunostomy). Finally, one study<sup>9</sup> was removed as it recruited patients from the same institution as another report<sup>31</sup>, but over a shorter period.

All of the nine manuscripts<sup>10,11,31–37</sup> selected for quantitative analysis were single-centre observational

studies (*Table 1*), mostly reporting on GDA pseudoaneurysms following pancreatoduodenectomy. One study<sup>33</sup> included both pancreatoduodenectomy and modified pylorus-preserving pancreatoduodenectomy, while another<sup>10</sup> included several pancreatic procedures. Data from 39 patients with GDA pseudoaneurysms were extracted from 14 studies for systematic review of clinical presentation and management (*Table 2*).

A total of 55 GDA pseudoaneurysms were identified in the postoperative period following 4227 pancreatic procedures, with a reported incidence of 1.3 (range 0.2–8.3) per cent (*Table 1*). Most patients who developed GDA pseudoaneurysm had a preceding complication in the postoperative period (14 of 21), including abscesses (6 patients), pancreatic fistulas (3) and pancreatic leaks (3). Three studies<sup>10,22,38</sup> reported the formation of pseudoaneurysms away from the cut edge of the pancreas and in the absence of pancreatic fistulas. Sentinel bleeding was reported in 14 of 20 patients (70 per cent). The median time for postoperative haemorrhage was at 15 (range 4–210) days.

Diagnostic procedures were reported for 21 patients; 18 GDA pseudoaneurysms were detected by angiography.

Thirty-five of the 39 patients (90 per cent) were treated using an endovascular approach. Nineteen (49 per cent) were managed using transarterial embolization (TAE) of the GDA via the common hepatic artery (CHA), and 14 (36 per cent) by selective embolization of the pseudoaneurysm. Stenting was employed in two patients (5 per cent), and only four (10 per cent) were treated by emergency laparotomy. The overall survival rate was 85 per cent (33 of 39).

## Discussion

The GDA is the most common site for pseudoaneurysm formation after pancreatic surgery<sup>9–11</sup>, and its rupture in the postoperative period has long been recognized as a cause of substantial morbidity and mortality<sup>7,8</sup>. GDA pseudoaneurysms are rare. The present analysis suggests that they occur in 0.2–8.3 per cent of pancreatic resections. It should be noted, however, that studies included in this review were all high-volume resectional centres.

In this series, two-thirds of the patients (4 of 21) had a preceding complication following pancreatic resection. Most authors favoured the hypothesis that lytic, enzyme-rich, pancreatic fluid from a pancreatic anastomotic leak could result in autodigestion of GDA vessel wall owing to its proximity to the pancreatic anastomosis.

Interestingly, a few studies<sup>10,22,38</sup> reported the formation of pseudoaneurysms at distance from the pancreatic anastomosis and in the absence of an overt pancreatic fistula, suggesting that minor iatrogenic injury, such as skeletonization of the vessel wall during extensive lymphadenectomy, may lead to vessel weakening and subsequent pseudoaneurysm formation.

Various techniques have been suggested to reduce the chance of pseudoaneurysm formation, including the 'wrapping' technique<sup>25,39–45</sup>, in which the exposed retroperitoneal vessels are covered with omentum or the falciform ligament. Others<sup>46</sup> have suggested leaving 1 cm at the origin of the GDA stump to minimize the likelihood of lytic pancreatic juices coming into contact with the vessel.

Recognition of a sentinel bleed may help in early management, this being a feature in most patients<sup>9,37,47</sup>. Although sentinel bleeding was associated with poor outcome in some series<sup>6,35</sup>, few authors discussed the importance of immediate angiography after a sentinel bleed to look for the possibility of a ruptured pseudoaneurysm<sup>6,37</sup>. Although angiography also has the added benefit of allowing transition to endovascular treatment, a number of reports noted that negative findings cannot be used to exclude a bleeding pseudoaneurysm<sup>26</sup>, as bleeding can be intermittent or

the rate of bleeding is below the detection limit of the equipment<sup>7,9,37,48,49</sup>.

Surgical intervention has been largely replaced by interventional radiology<sup>50–54</sup>. Some older studies<sup>26,55</sup> advocated surgery in the context of additional intra-abdominal complications such as pancreatic fistula, but more recent series<sup>11,36</sup> have documented the superiority of endovascular management. A recent meta-analysis<sup>56</sup> of non-randomized studies comparing endovascular management and laparotomy for delayed massive haemorrhage suggested lower complication and mortality rates in the endovascular group.

The endovascular management of pseudoaneurysms varied, reflecting the location and size of the pseudoaneurysm and probably institutional preferences for approach and embolization technique, and materials. TAE of the GDA was conducted via either the CHA or the superior mesenteric artery to achieve both proximal and distal occlusion, to exclude the pseudoaneurysm and prevent backflow from collateral circulation<sup>57</sup>. Such an approach should consider patency of the portal venous system<sup>41</sup> as TAE distal and proximal to the GDA pseudoaneurysm can cause complete occlusion of the CHA, leading to liver infarction (reported range 30–66 per cent)<sup>29,37,58</sup>, as well as hepatic failure and abscess formation<sup>58</sup>. Covered stents represented the alternative to TAE. The key advantage over TAE would be in maintaining patency of the CHA and reducing the risk of hepatic infarction, although accurate stent deployment might be technically more challenging and time-consuming than TAE<sup>36,57</sup>. Despite these issues, stenting seems to be preferred in more recent series, on the grounds that selective embolization of the GDA stump or pseudoaneurysm seems to be associated with high rates of recurrent bleeding<sup>36,42</sup>.

Limitations of this study include heterogeneity of the included studies, the descriptors used and study sizes. The absence of any prospective registers or clinical trials on this topic needs to be addressed.

## Disclosure

The authors declare no conflict of interest.

## References

- 1 Saeger HD, Schwall G, Trede M. Standard Whipple in chronic pancreatitis. In *Standards in Pancreatic Surgery*, Beger HG, Büchler M, Malfertheiner P (eds). Springer: Berlin, 1993; 385–391.
- 2 Cameron JL, Pitt HA, Yeo CJ, Lillemoe KD, Kaufman HS, Coleman J. One hundred and forty-five consecutive pancreaticoduodenectomies without mortality. *Ann Surg* 1993; **217**: 430–435.

- 3 Büchler MW, Friess H, Müller MW, Wheatley AM, Beger HG. Randomized trial of duodenum-preserving pancreatic head resection *versus* pylorus-preserving Whipple in chronic pancreatitis. *Am J Surg* 1995; **169**: 65–69.
- 4 Schlitt HJ, Schmidt U, Simunec D, Jäger M, Aselmann H, Neipp M *et al*. Morbidity and mortality associated with pancreatogastrostomy and pancreatojejunostomy following partial pancreatoduodenectomy. *Br J Surg* 2002; **89**: 1245–1251.
- 5 Yeo CJ, Cameron JL, Sohn TA, Lillemoe KD, Pitt HA, Talamini MA *et al*. Six hundred fifty consecutive pancreaticoduodenectomies in the 1990s: pathology, complications, and outcomes. *Ann Surg* 1997; **226**: 248–257.
- 6 Yekebas EF, Wolfram L, Cataldegirmen G, Habermann CR, Bogoevski D, Koenig AM *et al*. Postpancreatectomy hemorrhage: diagnosis and treatment: an analysis in 1669 consecutive pancreatic resections. *Ann Surg* 2007; **246**: 269–280.
- 7 Brodsky JT, Turnbull AD. Arterial hemorrhage after pancreatoduodenectomy. The ‘sentinel bleed’. *Arch Surg* 1991; **126**: 1037–1040.
- 8 Lerut JP, Gianello PR, Otte JB, Kestens PJ. Pancreaticoduodenal resection. Surgical experience and evaluation of risk factors in 103 patients. *Ann Surg* 1984; **199**: 432–437.
- 9 Lee HG, Heo JS, Choi SH, Choi DW. Management of bleeding from pseudoaneurysms following pancreaticoduodenectomy. *World J Gastroenterol* 2010; **16**: 1239–1244.
- 10 Fujii Y, Shimada H, Endo I, Yoshida K, Matsuo K, Takeda K *et al*. Management of massive arterial hemorrhage after pancreatobiliary surgery: does embolotherapy contribute to successful outcome? *J Gastrointest Surg* 2007; **11**: 432–438.
- 11 Adam G, Tas S, Cinar C, Bozkaya H, Adam F, Uysal F *et al*. Endovascular treatment of delayed hemorrhage developing after the pancreaticoduodenectomy procedure. *Wien Klin Wochenschr* 2014; **126**: 416–421.
- 12 Budzyński J, Meder G, Suppan K. Giant gastroduodenal artery pseudoaneurysm as a pancreatic tumor and cause of acute bleeding into the digestive tract. *Prz Gastroenterol* 2016; **11**: 299–301.
- 13 Miyazawa R, Kamo M, Nishiyama T, Ohigashi S, Yagihashi K. Covered stent placement using ‘pull-through’ technique for a gastroduodenal artery stump pseudoaneurysm after pancreaticoduodenectomy. *J Vasc Interv Radiol* 2016; **27**: 1743–1745.
- 14 Loveček M, Havlík R, Köcher M, Vomáčková K, Neoral C. Pseudoaneurysm of the gastroduodenal artery following pancreatoduodenectomy. Stenting for hemorrhage. *Wideochir Inne Tech Maloinwazyjne* 2014; **9**: 297–301.
- 15 Nakatsuka H, Sawatsubashi T, Morioka N, Shimizu T, Kanda T. [Use of the round ligament of the liver to prevent postpancreatectomy haemorrhage.] *Gan To Kagaku Ryobo* 2013; **40**: 1903–1905.
- 16 Mazza E, Abdulcadir D, Raspanti C, Acquafresca M. A challenging case of epigastric pain: diagnosis and mini-invasive treatment of a large gastroduodenal artery pseudoaneurysm. *BMJ Case Rep* 2012; **2012**: bcr0220125873.
- 17 Huang YK, Lu MS, Tsai FC, Ko PJ, Hsieh HC, Lin PJ. A forgotten complication following pancreatic resection. Visceral artery pseudo-aneurysms. *Saudi Med J* 2007; **28**: 973–975.
- 18 Noun R, Zeidan S, Tohme-Noun C, Smayra T, Sayegh R. Biliary ischemia following embolization of a pseudoaneurysm after pancreaticoduodenectomy. *JOP* 2006; **7**: 427–431.
- 19 Balducci G, Dente M, Ferri M, Rebonato A, La Torre M, Mercantini P. [Bleeding caused by pseudoaneurysm rupture after pancreaticoduodenectomy.] *G Chir* 2006; **27**: 318–320.
- 20 Santoro R, Carlini M, Carboni F, Nicolas C, Santoro E. Delayed massive arterial hemorrhage after pancreatoduodenectomy for cancer. Management of a life-threatening complication. *Hepatogastroenterology* 2003; **50**: 2199–2204.
- 21 Orsenigo E, De Cobelli F, Salvioni M, Cristallo M, Fiorina P, Del Maschio A *et al*. Successful endovascular treatment for gastroduodenal artery pseudoaneurysm with an arteriovenous fistula after pancreas transplantation. *Transpl Int* 2003; **16**: 694–696.
- 22 Sugimoto H, Kaneko T, Ishiguchi T, Takai K, Ohta T, Yagi Y *et al*. Delayed rupture of a pseudoaneurysm following pancreatoduodenectomy: report of a case. *Surg Today* 2001; **31**: 932–935.
- 23 Born LJ, Madura JA, Lehman GA. Endoscopic diagnosis of a pancreatic pseudoaneurysm after lateral pancreatojejunostomy. *Gastrointest Endosc* 1999; **49**: 382–384.
- 24 Teramoto K, Kawamura T, Takamatsu S, Noguchi N, Ariei S. A case of hepatic artery embolization and partial arterialization of the portal vein for intraperitoneal, hemorrhage after a pancreaticoduodenectomy. *Hepatogastroenterology* 2003; **50**: 1217–1219.
- 25 Ray S, Sanyal S, Ghatak S, Sonar PK, Das S, Khamrui S *et al*. Falciform ligament flap for the protection of the gastroduodenal artery stump after pancreaticoduodenectomy: a single center experience. *J Visc Surg* 2016; **153**: 9–13.
- 26 de Castro SM, Kuhlmann KF, Busch OR, van Delden OM, Laméris JS, van Gulik TM *et al*. Delayed massive hemorrhage after pancreatic and biliary surgery: embolization or surgery? *Ann Surg* 2005; **241**: 85–91.
- 27 Magge D, Zenati M, Lutfi W, Hamad A, Zureikat AH, Zeh HJ *et al*. Robotic pancreatoduodenectomy at an experienced institution is not associated with an increased risk of post-pancreatic hemorrhage. *HPB (Oxford)* 2018; **20**: 448–455.
- 28 Kalva SP, Yeddula K, Wicky S, Fernandez del Castillo C, Warshaw AL. Angiographic intervention in patients with a suspected visceral artery pseudoaneurysm complicating pancreatitis and pancreatic surgery. *Arch Surg* 2011; **146**: 647–652.

- 29 Gwon DI, Ko GY, Sung KB, Shin JH, Kim JH, Yoon HK. Endovascular management of extrahepatic artery hemorrhage after pancreatobiliary surgery: clinical features and outcomes of transcatheter arterial embolization and stent-graft placement. *AJR Am J Roentgenol* 2011; **196**: W627–W634.
- 30 Okuno A, Miyazaki M, Ito H, Ambiru S, Yoshidome H, Shimizu H *et al.* Nonsurgical management of ruptured pseudoaneurysm in patients with hepatobiliary pancreatic diseases. *Am J Gastroenterol* 2001; **96**: 1067–1071.
- 31 Jeong J, Choi SH, Choi DW, Heo JS, Kim DH, Lee H. Management of delayed arterial hemorrhage following pancreaticoduodenectomy: a single-center experience. *HPB (Oxford)* 2014; **16**: 133.
- 32 Yada K, Kawano Y, Komori Y, Masuda T, Hirashita T, Eguchi H *et al.* Perioperative outcomes of pancreatoduodenectomy in elderly patients. *J Gastroenterol Hepatol* 2011; **26**: 233.
- 33 Suzuki K, Mori Y, Komada T, Matsushima M, Ota T, Naganawa S. Stent-graft treatment for bleeding superior mesenteric artery pseudoaneurysm after pancreaticoduodenectomy. *Cardiovasc Intervent Radiol* 2009; **32**: 762–766.
- 34 Loveček M, Skalický P, Köcher M, Černá M, Prášil V, Holusková I *et al.* [Postpancreatectomy haemorrhage (PPH), prevalence, diagnosis and management.] *Rozhl Chir* 2016; **95**: 350–357.
- 35 Rajarathinam G, Kannan DG, Vimalraj V, Amudhan A, Rajendran S, Jyotibasud D *et al.* Post pancreaticoduodenectomy haemorrhage: outcome prediction based on new ISGPS Clinical severity grading. *HPB (Oxford)* 2008; **10**: 363–370.
- 36 Hur S, Yoon CJ, Kang SG, Dixon R, Han HS, Yoon YS *et al.* Transcatheter arterial embolization of gastroduodenal artery stump pseudoaneurysms after pancreaticoduodenectomy: safety and efficacy of two embolization techniques. *J Vasc Interv Radiol* 2011; **22**: 294–301.
- 37 Sato N, Yamaguchi K, Shimizu S, Morisaki T, Yokohata K, Chijiwa K *et al.* Coil embolization of bleeding visceral pseudoaneurysms following pancreatectomy: the importance of early angiography. *Arch Surg* 1998; **133**: 1099–1102.
- 38 Reber PU, Baer HU, Patel AG, Wildi S, Triller J, Büchler MW. Superselective microcoil embolization: treatment of choice in high-risk patients with extrahepatic pseudoaneurysms of the hepatic arteries. *J Am Coll Surg* 1998; **186**: 325–330.
- 39 Sato A, Yamada T, Takase K, Matsuhashi T, Higano S, Kaneda T *et al.* The fatal risk in hepatic artery embolization for hemostasis after pancreatic and hepatic surgery: importance of collateral arterial pathways. *J Vasc Interv Radiol* 2011; **22**: 287–293.
- 40 Gaudon C, Soussan J, Louis G, Moutardier V, Gregoire E, Vidal V. Late postpancreatectomy hemorrhage: predictive factors of morbidity and mortality after percutaneous endovascular treatment. *Diagn Interv Imaging* 2016; **97**: 1071–1077.
- 41 Tani M, Kawai M, Hirono S, Hatori T, Imaizumi T, Nakao A *et al.* Use of omentum or falciform ligament does not decrease complications after pancreaticoduodenectomy: nationwide survey of the Japanese Society of Pancreatic Surgery. *Surgery* 2012; **151**: 183–191.
- 42 Maeda A, Ebata T, Kanemoto H, Matsunaga K, Bando E, Yamaguchi S *et al.* Omental flap in pancreaticoduodenectomy for protection of splanchnic vessels. *World J Surg* 2005; **29**: 1122–1126.
- 43 Ramia JM, de la Plaza R, Adel F, Ramiro C, Arteaga V, Garcia-Parreño J. Wrapping in pancreatic surgery: a systematic review. *ANZ J Surg* 2014; **84**: 921–924.
- 44 Choi SB, Lee JS, Kim WB, Song TJ, Suh SO, Choi SY. Efficacy of the omental roll-up technique in pancreaticojejunostomy as a strategy to prevent pancreatic fistula after pancreaticoduodenectomy. *Arch Surg* 2012; **147**: 145–150.
- 45 Matsuda H, Sadamori H, Umeda Y, Shinoura S, Yoshida R, Satoh D *et al.* Preventive effect of omental flap in pancreaticoduodenectomy against postoperative pseudoaneurysm formation. *Hepatogastroenterology* 2012; **59**: 578–583.
- 46 Turrini O, Moutardier V, Guiramand J, Lelong B, Bories E, Sannini A *et al.* Hemorrhage after duodenopancreatectomy: impact of neoadjuvant radiochemotherapy and experience with sentinel bleeding. *World J Surg* 2005; **29**: 212–216.
- 47 Koukoutsis I, Bellagamba R, Morris-Stiff G, Wickremesekera S, Coldham C, Wigmore SJ *et al.* Haemorrhage following pancreaticoduodenectomy: risk factors and the importance of sentinel bleed. *Dig Surg* 2006; **23**: 224–228.
- 48 Shankar S, Russell RC. Haemorrhage in pancreatic disease. *Br J Surg* 1989; **76**: 863–866.
- 49 van Berge Henegouwen MI, Allema JH, van Gulik TM, Verbeek PC, Obertop H, Gouma DJ. Delayed massive haemorrhage after pancreatic and biliary surgery. *Br J Surg* 1995; **82**: 1527–1531.
- 50 Bassi C, Falconi M, Salvia R, Mascetta G, Molinari E, Pederzoli P. Management of complications after pancreaticoduodenectomy in a high volume centre: results on 150 consecutive patients. *Dig Surg* 2001; **18**: 453–457.
- 51 Robinson K, Rajebi MR, Zimmerman N, Zeinati C. Post-pancreaticoduodenectomy hemorrhage of unusual origin: treatment with endovascular embolization and the value of preoperative CT angiography. *J Radiol Case Rep* 2013; **7**: 29–36.
- 52 Johnson MA, Chidambaram S. Current management protocol in peripancreatic pseudoaneurysms. *Pancreatol* 2011; **11**: 40.
- 53 Arata MA, Cope C. Principles used in the management of visceral aneurysms. *Tech Vasc Interv Radiol* 2000; **3**: 124–129.
- 54 Saad NE, Saad WE, Davies MG, Waldman DL, Fultz PJ, Rubens DJ. Pseudoaneurysms and the role of minimally invasive techniques in their management. *Radiographics* 2005; **25**(Suppl 1): S173–S189.

- 55 Blanc T, Cortes A, Goere D, Sibert A, Pessaux P, Belghiti J *et al.* Hemorrhage after pancreaticoduodenectomy: when is surgery still indicated? *Am J Surg* 2007; **194**: 3–9.
- 56 Limongelli P, Khorsandi SE, Pai M, Jackson JE, Tait P, Tierris J *et al.* Management of delayed postoperative hemorrhage after pancreaticoduodenectomy: a meta-analysis. *Arch Surg* 2008; **143**: 1001–1007.
- 57 Ding X, Zhu J, Zhu M, Li C, Jian W, Jiang J *et al.* Therapeutic management of hemorrhage from visceral artery pseudoaneurysms after pancreatic surgery. *J Gastrointest Surg* 2011; **15**: 1417–1425.
- 58 Otah E, Cushin BJ, Rozenblit GN, Neff R, Otah KE, Cooperman AM. Visceral artery pseudoaneurysms following pancreatoduodenectomy. *Arch Surg* 2002; **137**: 55–59.