



## Achilles tendinopathy Doppler imaging and activity

Journal:	<i>International Journal of Sports Medicine</i>
Manuscript ID:	Draft
Manuscript Type:	Orthopedics & Biomechanics
Key word:	Achilles tendinopathy, Doppler Ultrasound, Ultrasound imaging

SCHOLARONE™  
Manuscripts

Peer Review

1  
2  
3  
4  
5  
6  
7  
8  
9  
10  
11  
12  
13  
14  
15  
16  
17  
18  
19  
20  
21  
22  
23  
24  
25  
26  
27  
28  
29  
30  
31  
32  
33  
34  
35  
36  
37  
38  
39  
40  
41  
42  
43  
44  
45  
46  
47  
48  
49  
50  
51  
52  
53  
54  
55  
56  
57  
58  
59  
60

# Doppler ultrasound signal in Achilles tendinopathy reduces immediately after activity

Malliaras P<sup>1,2</sup>, Chan O<sup>2</sup>, Grewal S<sup>1</sup>, Martinez De Albornoz Torrente P<sup>3</sup>, Morrissey D<sup>1,2</sup>, Maffulli N<sup>1,2</sup>

<sup>1</sup>Centre for Sports and Exercise Medicine, Queen Mary, University of London, United Kingdom

<sup>2</sup>London Independent Hospital, United Kingdom

<sup>3</sup>Hospital Fremap Majadahonda, Spain

## Abstract

Background: A relationship has been identified between vascularization on Doppler ultrasound (Doppler signal) and Achilles tendon pain. Doppler signal may increase minutes after prolonged activity, but the immediate effect is unknown. The study aim was to investigate the immediate effect of short term activity on Achilles tendon Doppler signal. Achilles tendinopathy patients (7 patients, 10 tendons) and asymptomatic controls (6 controls, 12 tendons) performed two activity tasks; a two minute continuous step task and one minute continuous calf raise task. Doppler signal was measured at rest and within a minute after each activity. The presence of Doppler signal was quantified using both semi quantitative (modified Ohberg scale; 0=no signal, 5=>90% of pathological area contains Doppler signal) and quantitative methods (pixel number). Doppler signal was present in 90% of symptomatic individuals and in none of the asymptomatic controls. The modified Ohberg scale and pixel number reduced significantly after both activity tasks and heart rate increased significantly ( $p<0.05$ ). Doppler signal in Achilles tendinopathy may decrease immediately after activities that load the calf muscle and increase heart rate, suggesting that this activity should be avoided prior to imaging to avoid false negative results.

Key terms: Achilles tendinopathy, Doppler ultrasound, Ultrasound imaging

## Introduction

Chronic Achilles pain is relatively common, particularly among athletes,<sup>23</sup> with the prevalence of Achilles tendinopathy in runners estimated to be 18%.<sup>20</sup> Tendinopathy is characterised by pain and decreased functional ability.<sup>12</sup> The histopathological features of tendon pathology are consistent with a failed healing response with a disarray in collagen, non-inflammatory hypercellularity, an increase in ground substance, and neurovascular ingrowth.<sup>4</sup>

1  
2  
3  
4  
5 The relationship between tendon pain and pathology is not straightforward; asymptomatic  
6 abnormalities on gray scale ultrasound are common, affecting up to 29% of Achilles tendons.<sup>9</sup>  
7 Doppler ultrasound allows visualisation of vascular structures within the tendon that may have  
8 diagnostic utility. Doppler signal has been associated with pain in several studies<sup>3,14,15,17,18</sup> and  
9 some studies show a stronger relationship with pain than gray scale ultrasound abnormality  
10 alone.<sup>15,8</sup> Other studies, however, show no relationship between Doppler signal<sup>8,23</sup> and pain, and  
11 some studies have identified Doppler signal in both normal and asymptomatic tendons.<sup>5</sup> This  
12 discrepancy may be explained by several factors that may influence Doppler signal detection.  
13 These include the stage of disease, cohort investigated (e.g. age, loading history), the  
14 ultrasound machine sensitivity and settings, the measurement technique (e.g. probe pressure,  
15 joint position), and activity level prior to testing<sup>5,7,8,15,17,23</sup>.

16  
17  
18  
19  
20  
21  
22  
23  
24  
25  
26  
27  
28  
29  
30  
31 There has been limited work concerning the effect of exercise on Doppler signal. Doppler signal  
32 has been shown to increase among pathological tendons after volleyball (patellar tendon)<sup>7</sup> and  
33 eccentric training (Achilles tendon)<sup>23</sup>. This is clinically relevant as activity prior to imaging may  
34 reduce false negatives in identifying Doppler signal. However, asymptomatic tendons may also  
35 increase or develop Doppler signal after running<sup>23</sup> or badminton<sup>6</sup> so loading tendons prior to  
36 imaging may reveal normal and asymptomatic tendons with Doppler signal (false positives). The  
37 relationship between activity and change in Doppler signal needs to be clarified as this may  
38 effect interpretation of imaging and imaging protocols. The primary objective of this study was to  
39 determine the Doppler signal response following two short duration bouts of activity involving calf  
40 loading and cardiovascular stress.  
41  
42  
43  
44  
45  
46  
47  
48  
49  
50  
51

## 52 53 54 55 **Method** 56 57 58 59 60

1  
2  
3 The study was conducted at the London Independent Hospital from January to May 2010.  
4  
5 Participants with Achilles tendinopathy were referred to the research team by a consultant  
6  
7 radiologist. The control population was recruited from staff and students within the Centre for  
8  
9 Sports and Exercise Medicine, Queen Mary, University of London. The study was approved by  
10  
11 the Queen Mary, University of London, Human Ethics Committee, and all participants provided  
12  
13 written informed consent.  
14  
15

16  
17  
18 Patients with Achilles tendinopathy were recruited if they were between 18-65 years old and had  
19  
20 a clinical and ultrasound diagnosis (abnormal gray scale) of mid-portion Achilles tendinopathy.  
21  
22 Controls were recruited if they were between 18-65 years old and did not have a history of  
23  
24 Achilles tendinopathy. Participants were excluded if they had a history of Achilles tendon  
25  
26 rupture, surgery, injections or direct trauma. Patients with insertional tendinopathy or co-existing  
27  
28 inflammatory arthropathies or lower limb radiculopathy were also excluded.  
29  
30  
31

32  
33 Participants completed a questionnaire collecting demographic data (age, gender, height,  
34  
35 weight, type of activity/sport played currently or before tendinopathy and hours played per week)  
36  
37 and a visual analogue scale (VAS) score assessing rest and activity pain in the Achilles tendon  
38  
39 over the previous two weeks (0=no pain, 10=worst imaginable). Pain and function was assessed  
40  
41 with a disease specific and validated outcome (Victorian Institute of Sport Assessment-Achilles  
42  
43 questionnaire; VISA-A).<sup>20</sup>  
44  
45  
46

#### 47 48 *Activity tasks*

49  
50 Each patient performed two activity tasks in a counterbalanced order. Prior to the first activity  
51  
52 task all patients rested for a minimum of 30 minutes. Half the subjects did one exercise first, and  
53  
54 the other half did the alternative exercise first. One task was designed to load the calf muscle  
55  
56 and involved 60 seconds of continuous ankle double-legged straight-knee calf raises over the  
57  
58  
59  
60

1  
2  
3 edge of a 20cm step, performed slowly (approximately 1 cycle every 2 seconds). The other task  
4  
5 was designed to stress the calf muscle and cardiovascular system and involved stepping onto  
6  
7 and off a 20cm step continuously for 120 seconds. Participants rested for a minimum of 20  
8  
9 minutes between activity tasks. Pilot testing suggested that this was sufficient to allow recovery  
10  
11 of heart rate and change in Doppler signal so ultrasound was not repeated prior to the second  
12  
13 activity task.  
14  
15

### 16 17 18 *Outcomes*

19  
20 Doppler ultrasound was measured prior to any activity (after a minimum 30 minute rest) and  
21  
22 immediately after each activity task (Figure 1). Each activity was performed in the ultrasound  
23  
24 scanning room and Doppler ultrasound was assessed within a minute of the completion of  
25  
26 activity tasks. Heart rate (HR) was assessed throughout the study using a HR monitor that  
27  
28 subjects wore around their chest (Polar F11, Polar Electro, Kempele, Finland). Heart rate was  
29  
30 recorded before and after each activity task.  
31  
32

33  
34  
35 An experienced consultant radiologist (OC) performed all ultrasound imaging. Gray scale  
36  
37 imaging (sagittal and axial plane) to assess the presence of pathology was performed to satisfy  
38  
39 the inclusion and exclusion criteria. Patients were positioned supine on the couch with their hip  
40  
41 externally rotated, knee flexed to 45 degrees and ankle plantigrade. The same ultrasound  
42  
43 machine, equipped with a 13 MHz linear high resolution probe was used for all measures  
44  
45 (Sonoline Elegra, Siemens, Erlangen, Germany). The power Doppler was set at a 1250 Hz pulse  
46  
47 repetition frequency with gain standardized to just below the level that produced random noise.  
48  
49 Pressure on the tendon from the probe was minimized to prevent vessel compression.  
50  
51 Intratendinous Doppler signal was measured in the sagittal plane and anteroposterior (AP)  
52  
53 tendon diameter (mm) was measured in the sagittal and transverse planes. Only intratendinous  
54  
55 Doppler signal was measured as this has been associated with tendon pain.<sup>14,7</sup> Doppler  
56  
57  
58  
59  
60

1  
2  
3 measures included the presence/absence and two measures of the quantity of Doppler signal.  
4  
5 First, the semi-quantitative modified Ohberg<sup>14</sup> scale ranging from 0 to 5 (0=no signal, 1=1 small  
6 vessel, 2=2 small vessels, 3=signal in 30-50% of the pathological area, 4=signal in 50-90% of  
7 the pathological area, 5=signal in >90% of the pathological area). Second, number of Doppler  
8 signal pixels (pixel number) was calculated from saved images. The areas of colour foci were  
9 traced using Adobe Photoshop CS3 (Adobe Systems Incorporated, California, USA) and  
10 transferred to color foci only images with a standard sized white background. Then Wolframs  
11 Mathematica 7.0 was used to derive the total number of color pixels by deciphering the  
12 numerical properties of the colored foci and subtracting them from the background.  
13  
14  
15  
16  
17  
18  
19  
20  
21  
22  
23  
24

### 25 *Data analysis*

26  
27 SPSS version 18 was used to explore and analyse data. Symptomatic and asymptomatic  
28 tendons were separated for all analyses. Non-parametric tests were used given the small  
29 sample size and non-normal distributions. Change in heart rate and the quantity of Doppler  
30 signal (Modified Ohberg and pixel number) pre- and post each activity task was investigated  
31 using the Wilcoxin's matched pairs signed rank test. Statistical significance was defined as a p  
32 value of 0.05 or less.  
33  
34  
35  
36  
37  
38  
39  
40  
41

### 42 **Results**

43  
44 Thirteen subjects participated in the study. There were ten symptomatic tendons among seven  
45 patients (6 men, 1 woman) with a mean duration of symptoms of 12 months (range 3-24  
46 months). VISA-A scores, activity VAS, and rest VAS produced medians of 62 (IQR=59-72), 6  
47 (IQR=4-6) and 3 (IQR=2-4), respectively. There were twelve asymptomatic tendons among six  
48 participants (6 men, 0 women). Demographic data are presented in Table 1. Asymptomatic  
49 participants were significantly younger than symptomatic participants ( $p < 0.01$ ). There were no  
50 other differences between the groups. The median AP tendon diameter was significantly greater  
51  
52  
53  
54  
55  
56  
57  
58  
59  
60

1  
2  
3 among symptomatic tendons (8.2 mm, IQR=6.7-9.0) compared with asymptomatic tendons (4.3  
4 mm, IQR=3.7-4.7) ( $p<0.01$ ). Hypoechoogenicity was present in all symptomatic tendons and in  
5 one of the control tendons. Doppler signal was present at rest in 90% of the symptomatic  
6 tendons and none of the control tendons.  
7  
8  
9  
10

11  
12  
13  
14 Table 1. INSERTED HERE  
15  
16  
17

18  
19 *Heart rate and Doppler signal following activity*

20  
21 There was a significant increase in heart rate between baseline (median=68 bpm, IQR=61-84)  
22 immediately after both the calf raise (median=89 bpm, IQR=84-98,  $p<0.01$ ) and stepping  
23 activity tasks (median=140 bpm, IQR=136-161,  $p<0.01$ ). Heart rate was significantly greater  
24 following the step compared with the calf raise test ( $p<0.01$ ).  
25  
26  
27  
28  
29  
30  
31  
32  
33

34 There was no Doppler signal identified among asymptomatic tendons before or after activity,  
35 therefore only data for symptomatic tendons will be presented. The modified Ohberg score  
36 decreased significantly between baseline (median=3, IQR=1-3) and following both the calf raise  
37 (median=1, IQR=0.5-2.5,  $p=0.01$ , Figure 1) and stepping activity tasks (median=1, IQR=0-2,  
38  $p=0.02$ , Figure 2). Doppler signal resolved in three tendons after the stepping task (Figure 1)  
39 and in two tendons after the calf raise task (Figure 2). Baseline pixel number (median=3416,  
40 IQR=1048-11766) decreased significantly following both the calf raise (median=886, IQR=323-  
41 3568,  $p<0.01$ ) and stepping activity tasks (median=886, IQR=0-2208,  $p<0.01$ ) (Figure 3). There  
42 was no significant difference between the modified Ohberg scores or pixel number after each  
43 activity task (modified Ohberg,  $p=0.26$ ; pixel number,  $p=0.56$ ). An example of Doppler signal  
44 resolving (grade 1 to grade 0) among one symptomatic participant is shown in Figure 4.  
45  
46  
47  
48  
49  
50  
51  
52  
53  
54  
55  
56  
57  
58  
59  
60



## Discussion

The primary objective of this study was to investigate the immediate effect of activity on Doppler signal among symptomatic and asymptomatic tendons. At rest, we found Doppler signal present in 9 of the 10 (90%) symptomatic tendons, and no signal registered in any of the control tendons. In the symptomatic tendons, there was a significant decrease in Doppler signal (pixel number and modified Ohberg score) immediately after performing the calf raise and stepping activity tasks. There was complete resolution in Doppler signal in three tendons after the stepping task (Figure 1) and two tendons after the calf raise task (Figure 2). Heart rate increased after both activities, more so after the stepping task that was designed to offer greater challenge to the cardiovascular system. These findings suggest that short-term activity that loads the calf-Achilles musculotendinous unit and increases heart rate immediately prior to ultrasound imaging may reduce or even lead to resolution of Doppler signal among some tendons. This potentially increases false negatives in detecting Doppler signal, which has been associated with pain among pathological tendons<sup>3,11,14,15,17</sup>. Although these findings need to be confirmed, it appears that rest from activity immediately prior to loading may be beneficial in detecting Doppler signal in pathological Achilles tendons. Rest from activity prior imaging may also reduce the risk of Doppler appearing in normal tendons, as has previously been demonstrated (false positives)<sup>23,6</sup>.

Doppler detection may be affected by several factors, including machine sensitivity and settings, prior activity, patient's age, imaging position as well as probe pressure on the skin<sup>5,7,8,23,13,15,17</sup>.

Further work is needed to identify loading protocols that reliably identify Doppler signal in pathological but not normal tendons. These protocols may be different among machines with different sensitivities. For example, prolonged activity prior to loading may increase Doppler

1  
2  
3 signal<sup>6,7</sup> and this may be beneficial among less sensitive machines (e.g. portable machines) that  
4  
5 are often used in small sports medicine clinics.  
6  
7

8  
9  
10 Our finding of decreased Doppler signal among pathological tendons immediately post activity  
11 differs to the Boessen et al. (2006)<sup>5</sup> study, in which Doppler signal increased in 16 of 20 (80%)  
12 asymptomatic tendons after running, and there was a significant increase in Doppler signal after  
13 eccentric calf muscle exercise among symptomatic tendons that had Doppler signal below the  
14 median value. Differential response of Doppler signal to exercise between studies may be  
15 explained by the timing of ultrasound imaging. In the current study, exercise and imaging was  
16 performed in the same room to ensure that imaging was performed within 60 seconds of  
17 exercise completion. In the study by Boessen et al<sup>5</sup> the time between exercise and imaging is  
18 not specified but this is likely to have been several minutes (personal communication with  
19 authors). If blood flow is reduced immediately following activity, rest post activity may allow re-  
20 establishment of tendon Doppler signal. Other studies have shown an increase in Doppler signal  
21 among pathological and normal tendons after prolonged (>30 minutes) of aerobic activity  
22 (volleyball, badminton).<sup>6,7</sup> More prolonged activity may be required to cause an increase in  
23 Doppler signal. Both activities in the current study did lead to an increase in heart rate (although  
24 modest after the calf raise task), but this may not been prolonged enough to lead to increase in  
25 Doppler signal.  
26  
27  
28  
29  
30  
31  
32  
33  
34  
35  
36  
37  
38  
39  
40  
41  
42  
43  
44  
45

46 The decrease in Doppler signal was in contrast to the expected increase in muscle and tendon  
47 blood flow increases with exercise,<sup>22, 10</sup>. However, it is known that there is a hypoxic environment  
48 in muscle at the onset of exercise and this provides the stimulus for vasodilation and increase in  
49 blood flow<sup>19</sup>. Exercising time in this study (60 - 120 sec) may not have been sufficient to induce  
50 the sufficient cardiovascular response and vasodilatation to increase muscle and tendon blood  
51 flow. Indeed, the cardiovascular response after the calf raise task was modest. Further,  
52  
53  
54  
55  
56  
57  
58  
59  
60

1  
2  
3 Langberg et al. (1999)<sup>10</sup> observed a 2-3 fold increase in peritendinous blood flow in intermittently  
4  
5 exercising normal tendons, but the response of pathological tendons is unclear. Hypoxia may  
6  
7 stimulate neovascularisation<sup>1</sup>, and hypoxia increases angiogenesis related growth factors in rat  
8  
9 tenocytes.<sup>16</sup> It is possible that there is a prolonged hypoxic response among exercising  
10  
11 pathological tendons that may be one of the drivers for neovascularisation in tendon pathology.  
12  
13

14  
15  
16 Although there was a greater increase in heart rate after the stepping task, this does not clarify  
17  
18 the relationship between change in heart rate and Doppler signal as there was no difference in  
19  
20 the change in Doppler signal following either task. Further, both tasks stressed the  
21  
22 cardiovascular system and loaded the calf muscle, even though heart rate response was modest  
23  
24 with the calf raise task. The small sample size precluded investigation of the association  
25  
26 between change in Doppler signal and change in heart rate. Whether calf loading or  
27  
28 cardiovascular stress has a greater influence on Doppler signal is worthy of further investigation  
29  
30 as this may influence Doppler imaging protocols.  
31  
32

33  
34  
35 This is a small study with some limitations. We did not re-scan people after the first activity task  
36  
37 to ensure that Doppler signal returned to baseline levels. Even though we had pilot data to  
38  
39 suggest that the time period of rest was sufficient for Doppler flow to return baseline, it is  
40  
41 possible that among some participants it did not. In order to make sure that one activity was not  
42  
43 causing a systematic decrease in Doppler signal we counterbalanced the order of activity tasks,  
44  
45 with half of the participants performing one activity first while the others performing the other  
46  
47 activity. Furthermore, resolution in Doppler signal (modified Ohberg score = 0) occurred in  
48  
49 different participants after each activity task, suggesting no systemic effect of one activity task on  
50  
51 another. Reliability and validity of the Modified Ohberg scale has not been established although  
52  
53 it did change concurrently with the pixel number in the current study. Other limitations include  
54  
55 the fact that controls were significantly younger than patients with Achilles tendinopathy, and this  
56  
57  
58  
59  
60

1  
2  
3 may partly explain the lack of Doppler signal among the controls. The radiologist was not blind to  
4  
5 the participants' symptomatic status so experimenter bias is possible. Lack of standardisation of  
6  
7 Doppler settings and the sensitivity of Doppler machines needs to be considered when  
8  
9 comparing findings of different studies.  
10

11  
12  
13  
14 In conclusion, this study demonstrated that Doppler signal in Achilles tendinopathy may  
15  
16 decrease immediately after activities that load the calf and increase heart rate. This finding  
17  
18 suggests that rest from activity immediately prior to imaging may be beneficial in detecting  
19  
20 Doppler signal in pathological Achilles tendons. The factors that influence change in Doppler  
21  
22 signal post activity (e.g. type and duration of activity, cardiovascular response) need to be  
23  
24 explored as this has implications for Doppler imaging protocols.  
25  
26  
27  
28  
29  
30  
31  
32  
33  
34  
35  
36  
37  
38  
39  
40  
41  
42  
43  
44  
45  
46  
47  
48  
49  
50  
51  
52  
53  
54  
55  
56  
57  
58  
59  
60

## References

1. Alfredson H, Ohberg L, Forsgren S. (2003) Is vasculo-neural ingrowth the cause of pain in chronic Achilles tendinosis? An investigation using ultrasonography and colour Doppler, immunohistochemistry, and diagnostic injections. *Knee Sports Surg Traumatol Arthrosc.* 11(5):334-333
2. Alfredson, H. (2005) The chronic painful Achilles and patellar tendon: research on basic biology and treatment. *Scand J Med Sci Sports.* 15(4):252-259.
3. Alfredson H, Öhberg L. (2005) Sclerosing injections to areas of neo-vascularisation reduce pain in chronic Achilles tendinopathy: a double-blind randomised controlled trial. *Knee Surg Sports Traumatol Arthrosc.* 13(4):338-344.
4. Astrom M, Rausing A. (1995) Chronic Achilles Tendinopathy: A survey of Surgical and Histopathologic Findings. *Clin Orthop Relat Res.* 316:151-164.
5. Boesen MI, Koenig MJ, Torp-Pedersen S, Bliddal H, Langberg H. (2006) Tendinopathy and Doppler activity: the vascular response of the Achilles tendon to exercise. *Scand J Med Sci Sports.* 16(6):463-469.
6. Boesen M, Boesen A, Koenig J, Bliddal H, Torp-Pedersen S. (2006) Ultrasonographic Investigation of the Achilles tendon in Elite Badminton players Using Colour Doppler. *Am J Sports Med.* 34(12):2013- 2021.
7. Cook JL, Kiss ZS, Ptasznik R, Malliaras P. (2005) Is vascularity more evident after exercise? Implications for tendon imaging. *Am J Roentgenol.* 185(5):1138-1140.
8. De Vos RJ, Weir A, Cobben LP, Tol JL. (2007) The value of power Doppler ultrasonography in Achilles tendinopathy: a prospective study. *Am J Sports Med.* 35(10):1696-1701.
9. Fredberg U, Bolvic L. (2002) Significance of ultrasonographically detected asymptomatic tendinosis in the patellar and Achilles tendons of elite soccer players: a longitudinal study. *Am J Sports Med.* 30(4):488-491.
10. Langberg H, Skovgaard D, Karamouzis M, Bülow J, Kjaer M. (1999) Metabolism and inflammatory mediators in the peritendinous space measured by microdialysis during intermittent isometric exercise in humans. *J Physiol.* 515:919-927.
11. Lind B, Ohberg L, Alfredson H. (2006) Sclerosing polidocanol injections in mid-portion Achilles tendinosis: Remaining good clinical results and decreased tendon thickness at 2-year follow-up. *Knee Surg Traumatol Arthrosc.* 14(12):1327-1332.
12. Maffulli N, Khan KM, Puddu G. (1998) Overuse tendon conditions: time to change a confusing terminology. *Arthroscopy.* 14(8):840-843.
13. Orchard JW, Read JW, Anderson IJF. (2005) The use of diagnostic imaging in sports medicine. *Med J Aust.* 183(9):482-486.
14. Öhberg L, Alfredson H. (2002) Ultrasound guided sclerosis of neovessels in painful chronic Achilles tendinosis: pilot study of a new treatment. *Br J Sports Med.* 36(3):173-177.
15. Peers KHE, Brys PPM, Lysens RJJ. (2003) Correlation between power Doppler ultrasonography and clinical severity in Achilles tendinopathy. *Int Orthop.* 27(3):180-183.
16. Pufe T, Petersen W, Tillman B, Mentlein R. (2001) The angiogenic peptide vascular endothelial growth factor is expressed in foetal and ruptured tendons. *Virchows Arch.* 439(4):579-585.
17. Reiter M, Ulreich N, Dirisamer A, Tscholakoff D, Bucek RA. (2004) Colour and Power Doppler Sonography in Symptomatic Achilles Tendon Disease. *Int J Sports Med.* 25(4):301-305.
18. Richards PJ, Win T, Jones PW. (2005) The distribution of microvascular response in Achilles tendonopathy assessed by color and power Doppler. *Skeletal Radiol.* 34(6):336-342.
19. Richardson, R. S., Newcomer, S. C. and Noyeswski, E. A. (2001). Skeletal muscle intracellular PO(2) assessed by myoglobin desaturation: response to graded exercise. *J. Appl. Physiol.* 91:2679-2685.

- 1  
2  
3 20. Robinson JM, Cook JL, Purdam C, Visentini P, Ross J, Maffulli N, Taunton J, Khan K. (2001)  
4 The VISA-A questionnaire: a valid and reliable index of the clinical severity of Achilles  
5 tendinopathy. Br J Sports Med. 35(5):335–341.  
6 21. Rolf C, Movin T. (1997) Etiology, histopathology, and outcome of surgery in achillodynia.  
7 Foot Ankle Int. 18(9):565–569.  
8 22. Saltin B, Radegran G, Koskolou MD, Roach RC. (1998) Skeletal muscle blood flow in  
9 humans and its regulation during exercise. Acta Physiol Scand. 162(3):421-436.  
10 23. Zanetti M, Metzdorf A, Kundert HP, Zollinger H, Vienne P, Seifert B, Hodler J. (2003)  
11 Achilles tendons: clinical relevance of neovascularization diagnosed with power Doppler US.  
12 Radiology. 227(2):556-560.  
13  
14  
15  
16  
17  
18  
19  
20  
21  
22  
23  
24  
25  
26  
27  
28  
29  
30  
31  
32  
33  
34  
35  
36  
37  
38  
39  
40  
41  
42  
43  
44  
45  
46  
47  
48  
49  
50  
51  
52  
53  
54  
55  
56  
57  
58  
59  
60

Peer Review

Table 1. Demographic data (median (IQR)) among symptomatic and asymptomatic tendons

	Symptomatic, n=7	Asymptomatic, n=6
Age (years)*	46 (40-49)	23 (22-26)
Height (cm)	174(172-178)	179 (178-183)
Weight (kg)	73 (71-79)	77 (67-82)
Weekly activity (hrs)	9.5 (2-19)	4.0 (0-15)

\*Significant difference between the groups

For Peer Review

1  
2  
3  
4  
5  
6  
7  
8  
9  
10  
11  
12  
13  
14  
15  
16  
17  
18  
19  
20  
21  
22  
23  
24  
25  
26  
27  
28  
29  
30  
31  
32  
33  
34  
35  
36  
37  
38  
39  
40  
41  
42  
43  
44  
45  
46  
47  
48  
49  
50  
51  
52  
53  
54  
55  
56  
57  
58  
59  
60

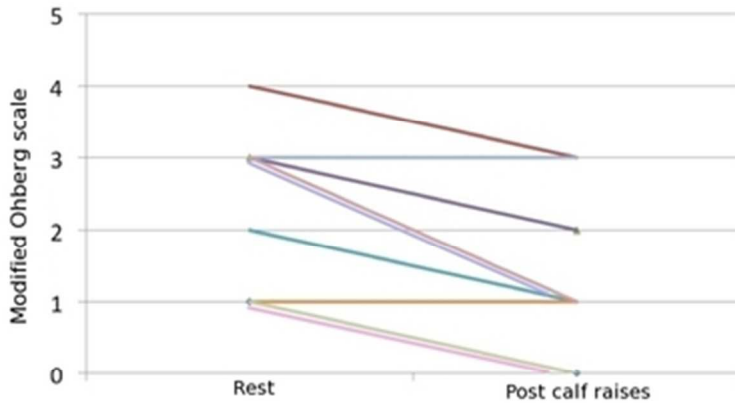


Figure 1. Change in modified Ohberg scale after the calf raise task

32x20mm (300 x 300 DPI)

Peer Review



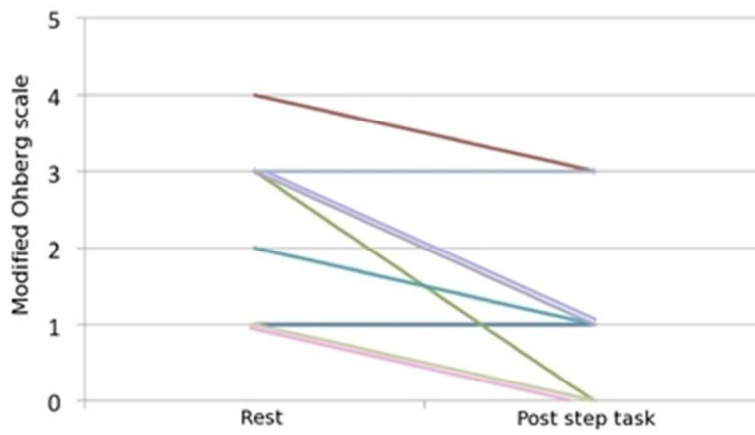


Figure 2. Change in modified Ohberg scale after stepping task

33x21mm (300 x 300 DPI)

Peer Review

1  
2  
3  
4  
5  
6  
7  
8  
9  
10  
11  
12  
13  
14  
15  
16  
17  
18  
19  
20  
21  
22  
23  
24  
25  
26  
27  
28  
29  
30  
31  
32  
33  
34  
35  
36  
37  
38  
39  
40  
41  
42  
43  
44  
45  
46  
47  
48  
49  
50  
51  
52  
53  
54  
55  
56  
57  
58  
59  
60

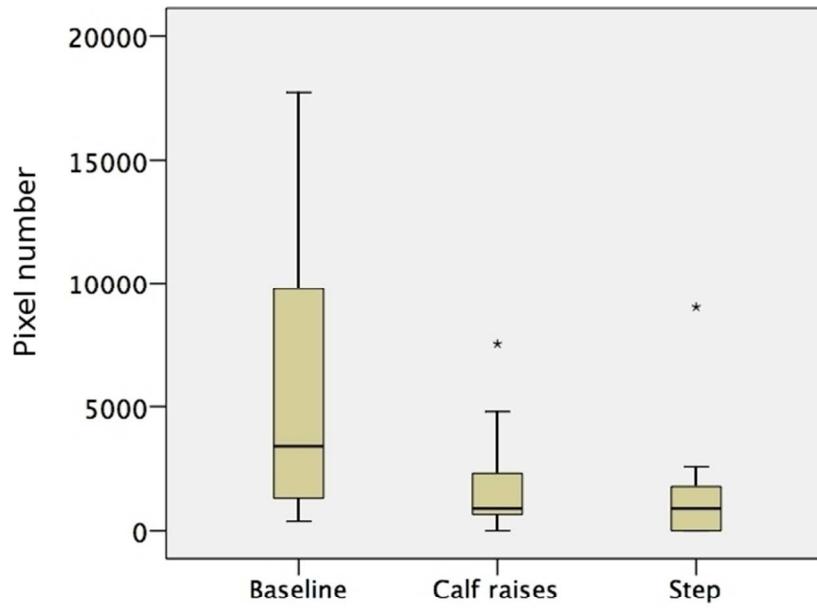


Figure 3. Pixel number at baseline and after each activity task

263x189mm (72 x 72 DPI)

Review

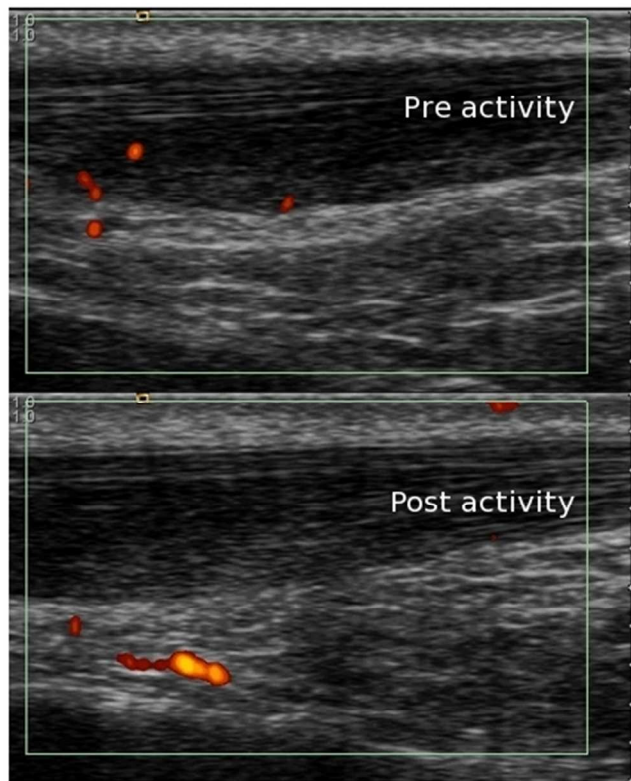


Figure 4. Doppler signal pre and post activity for one participant (Doppler signal is seen to resolve within the tendon and increase outside of the tendon)

57x52mm (300 x 300 DPI)

ew