

Neil MacBeth  
Anna Trullenque-Eriksson  
Nikolaos Donos  
Nikos Mardas

## Review

# Hard and soft tissue changes following alveolar ridge preservation: a systematic review

### Authors' affiliations:

Neil MacBeth, Defence Primary Health Care and Centre for Oral Clinical Research, Institute of Dentistry, Barts & The London School of Medicine & Dentistry, Queen Mary University of London (QMUL), London, UK  
Anna Trullenque-Eriksson, Nikolaos Donos, Centre for Oral Clinical Research, Institute of Dentistry, Barts & The London School of Medicine & Dentistry, Queen Mary University of London (QMUL), London, UK  
Nikos Mardas, Center for Adult Health Sciences, Institute of Dentistry, Barts & The London School of Medicine & Dentistry, Queen Mary University of London (QMUL), London, UK

### Corresponding author:

Professor Nikos Donos, DDS, MS, FHEA, FDSRCS(Engl.), PhD  
Head of Centre for Oral Clinical Research, Institute of Dentistry, Barts & The London School of Medicine & Dentistry, Queen Mary University of London (QMUL), Turner Street, London E1 2AD, UK  
Tel.: +44 (0) 20 7882 3063  
e-mail: n.donos@qmul.ac.uk

**Key words:** alveolar ridge preservation, gingival tissue, histology, tooth extraction

### Abstract

**Objective:** Two focused questions were addressed within this systematic review. Q1) What is the effect of alveolar ridge preservation on linear and volumetric alveolar site dimensions, keratinised measurements, histological characteristics and patient-based outcomes when compared to unassisted socket healing. Q2) What is the size effect of these outcomes in three different types of intervention (guided bone regeneration, socket grafting and socket seal).

**Materials and methods:** An electronic search (MEDLINE, EMBASE, Cochrane Central Register LILACS, Web of Science) and hand-search was conducted up to June 2015. Randomised controlled trials (RCT) and controlled clinical trials (CCT); with unassisted socket healing as controls: were eligible in the analysis for Q1. RCTs, CCTs and large prospective case series with or without an unassisted socket healing as control group were eligible in the analysis for Q2.

**Results:** Nine papers (8 RCTs and 1 CCTs) were included in the analysis for Q1 and 37 papers (29 RCTs, 7 CCTs and 1 case series) for Q2. The risk for bias was unclear or high in most of the studies. Q1: the standardised mean difference (SMD) in vertical mid-buccal bone height between ARP and a non-treated site was 0.739 mm (95% CI: 0.332 to 1.147). The SMD when proximal vertical bone height and horizontal bone width was compared was 0.796mm (95% CI: -1.228 to 0.364) and 1.198 mm (95% CI: -0.0374 to 2.433). Examination of ARP sites revealed significant variation in vital and trabecular bone percentages and keratinised tissue width and thickness. Adverse events were routinely reported, with three papers reporting a high level of complications in the test and control groups and two papers reporting greater risks associated with ARP. No studies reported on variables associated with the patient experience in either the test or the control group. Q2: A pooled effect reduction (PER) in mid-buccal alveolar ridge height of -0.467 mm (95% CI: -0.866 to -0.069) was recorded for GBR procedures and -0.157 mm (95% CI: -0.554 to 0.239) for socket grafting. A proximal vertical bone height reduction of -0.356 mm (95% CI: -0.490 to -0.222) was recorded for GBR, with a horizontal dimensional reduction of -1.45 mm (95% CI: -1.892 to -1.008) measured following GBR and -1.613 mm (95% CI: -1.989 to -1.238) for socket grafting procedures. Five papers reported on histological findings after ARP. Two papers indicated an increase in the width of the keratinised tissue following GBR, with two papers reporting a reduction in the thickness of the keratinised tissue following GBR. Histological examination revealed extensive variations in the treatment protocols and biomaterials materials used to evaluate extraction socket healing. GBR studies reported a variation in total bone formation of  $47.9 \pm 9.1\%$  to  $24.67 \pm 15.92\%$ . Post-operative complications were reported by 29 papers, with the most common findings soft tissue inflammation and infection.

**Conclusion:** ARP results in a significant reduction in the vertical bone dimensional change following tooth extraction when compared to unassisted socket healing. The reduction in horizontal alveolar bone dimensional change was found to be variable. No evidence was identified to clearly indicate the superior impact of a type of ARP intervention (GBR, socket filler and socket seal) on bone dimensional preservation, bone formation, keratinised tissue dimensions and patient complications.

### Date:

Accepted 21 May 2016

### To cite this article:

MacBeth N, Trullenque-Eriksson A, Donos N, Mardas N. Hard and soft tissue changes following alveolar ridge preservation: a systematic review. *Clin. Oral Impl. Res.* 00, 2016, 1-22  
doi: 10.1111/clr.12911

Alveolar bone and soft tissue remodelling is a normal physiological response following tooth extraction. These tissue changes have been recorded as leading to a 40-60%

decrease in the height and the width of the residual alveolar ridge (Johnson 1969; Farmer & Darby 2014), narrowing of the keratinised mucosa and reduction in the volumetric soft

tissue thickness (Tarnow et al. 1996; Schropp et al. 2005; Darby et al. 2009; Thoma et al. 2009). The resorption process varies greatly amongst individual patients and tooth position and may be affected by several factors such as the presence of infection, previous periodontal disease, the extent of a traumatic injury and the number or the thickness of the bony socket walls (Garg 2001). An equilibrium is reached approximately 3–4 months post-extraction, resulting in a bone and soft tissue level that is lower than that of the neighbouring teeth as complete regeneration of the socket site never occurs (Amler 1969).

To reduce the loss of alveolar bone to an acceptable level, several alveolar ridge preservation (ARP) techniques' procedures have been proposed (Wang et al. 2004; Horvath et al. 2013). These have included the minimally traumatic extraction of a tooth, followed by immediate grafting of the extraction sockets using particulate bone grafts or substitutes, guided bone regeneration (GBR) with or without bone grafts or substitutes (Adriaens & Van Stede 1998; Iasella et al. 2003; Mardas et al. 2010) and a socket seal technique using different tissue graft materials (Lekovic et al. 1998; Bartee 2001; Jung et al. 2004; Araujo et al. 2015). The use of grafting materials as an adjunct to GBR or socket seal techniques is based on the assumption that this material may be useful not only in prohibiting membrane or soft tissue graft collapse into the socket area but also in enhancing new bone formation through osteoinduction and osteoconduction.

Direct grafting and augmentation of the extraction socket has been proposed using autogenous bone (Becker et al. 1994), demineralised freeze-dried bone allograft (Becker et al. 1994; Becker et al. 1996; Froum et al. 2002), mineralised freeze-dried bone allograft (Feuille et al. 2003a,b), deproteinised bovine bone (Artzi et al. 2000 and Mardas et al. 2010), alloplastic polymers (Gross 1995 and Serino et al. 2003), bioactive glasses (Froum et al. 2002) and composite ceramic materials (Mardas et al. 2010). Although these bone substitutes were able to maintain the tissue contours in extraction sites, the conservancy of the gingival and bone tissue was variable. Marked differences in the quantity and the quality of the regenerated tissue have been reported, with the presence of the graft sometimes identified as interfering with the normal healing process (Froum et al. 2002; Mardas et al. 2010; Horvath et al. 2013; Hsun-Liang et al. 2013).

The preservation and regeneration of the gingival tissue is also important as it helps to

establish an ideal functional and aesthetic foundation, before prosthetic rehabilitation occurs (Seibert 1983; Studer et al. 2000; Jung et al. 2004; Prato et al. 2004). Although there is recognition that various ARP techniques can be used to preserve and promote alveolar bone and soft tissue development in the extraction socket area (Vignoletti et al. 2012; Wang & Lang 2012; De Risi et al. 2013; Horvath et al. 2013; Avila-Ortiz et al. 2014; Morjaria et al. 2014), heterogeneity of the published data has led Vignoletti et al. (2012), Horvath et al. (2013), Mardas et al. (2015) to conclude that the clinical outcome and prosthetic options available following ARP are inconclusive.

This systematic review and meta-analysis have been designed to investigate the effects of alveolar ridge preservation on bone and gingival tissue site dimensions, keratinised tissue width, histological bone characteristics and patient-based outcomes. It was designed as an extension and update of the systematic reviews undertaken by Horvath et al. (2013) Mardas et al. (2015).

## Material and methods

A detailed protocol was developed based on the design of a previous systematic review undertaken as a component of the 4th EAO consensus. This study reviewed therapeutic concepts for improving dental implant outcomes following tooth extraction (Mardas et al. 2015).

### Focused question 1

The main focused question of this systematic review was as follows: "Is there any additional benefit of alveolar ridge preservation techniques over unassisted healing in terms of the following: (i) horizontal and vertical alveolar ridge dimensions, (ii) soft tissue conservancy measured through linear and volumetric analysis, (iii) histological characteristics of the bone, (iv) keratinised tissue dimensions and (V) patient-based outcomes?"

### Focused question 2

This question was designed to examine data published in case series and in controlled clinical studies, where unassisted socket healing had not been used as a control group. It aimed to examine the effects of different ARP procedures and to address a second focused question: "what are the estimated size effects on (i) horizontal and vertical alveolar ridge dimensions, (ii) gingival tissue

conservancy measured through linear and volumetric dimensional changes, (iii) histological characteristics of the bone, (iv) keratinised tissue dimensions and (V) patient-based outcomes, following different alveolar ridge preservation techniques?"

### Types of studies

For *focused question 1*, only longitudinal prospective studies, that is RCTs and CCTs with unassisted socket healing as a control group, were included in the meta-analysis.

For *focused question 2*, in addition to the previous studies, RCTs, CCTs and large prospective case series without an unassisted healing control group were included in the meta-analysis.

### Populations of studies

Healthy individuals, without any age limit, underwent any type of ARP following permanent tooth extraction. Studies including smokers and patients with a history of periodontal disease were not excluded.

### Types of interventions

#### Test group

Studies reporting on any of the following ARP interventions were included: (i) socket grafting with autographs, allografts, xenografts, alloplast and substitutes with biologically active materials (growth factors); (ii) GBR with various barrier membranes and combinations of the above grafting materials; and (iii) socket seal procedures using a combination of soft tissue graft and the above grafting materials.

#### Control group

The control group for focused question 1 was unassisted socket healing following atraumatic tooth extraction without any other intervention.

### Outcome variables

For both focused questions, the following outcome variables were evaluated:

1. Linear and/or volumetric changes in vertical alveolar bone height.
2. Linear and/or volumetric changes in alveolar bone width.
3. Soft tissue dimensional changes.
4. Histological characteristics of new bone formation.
5. Changes in keratinised tissue width and thickness.
6. Post-operative complications and patient-based outcomes.

### Risk of bias and methodological quality assessment

An assessment of the risk of bias within the study and the research methodology was undertaken using a modification of the Cochrane tool proposed by Higgins & Green (2011). No attempt was made to differentiate between non-randomised and randomised studies as both randomised and non-randomised clinical trials were included in the systematic review. The levels of bias were classified as low risk, unclear risk or high risk, with six parameters: allocation concealment, blinding of participants and personnel, blinding of outcome assessment, incomplete outcome data, selective reporting and other sources of bias evaluated. If all the parameters were judged as low, the study was at low risk of bias. If at least one parameter was judged as unclear or as at high risk of bias, the studies were included at unclear or high risk of bias, respectively.

### General inclusion criteria

1. Studies on healthy individuals, without any age limit, who underwent ARP following tooth extraction.
2. Studies providing information on bone and soft tissue characteristics and patient-based outcomes following ARP at an extraction socket site.

### General exclusion criteria

1. Retrospective studies.
2. Studies on medically compromised patients or under specific medication.
3. Studies reporting on immediate implant placement as a method for ARP.
4. Studies reporting solely on third molar extractions.
5. Publications reporting data on the same sample and procedures as other publications.

### Specific inclusion criteria for focused question 1

1. Longitudinal prospective studies, that is RCTs and CCTs where one of the above-mentioned types of interventions was carried out in the test group and where unassisted socket healing was used as a control group.
2. Studies reporting on a minimum of 10 patients per group.
3. Follow-up time longer than 3 months.

### Specific inclusion criteria for focused question 2

1. Longitudinal prospective studies, that is RCTs, CCTs, cohort studies where one or more of the above-mentioned types of

interventions was carried out, with or without unassisted socket healing as a control group, and prospective case series.

2. Controlled studies reporting on a minimum of 10 patients per group, or case series reporting on a minimum of 20 patients.
3. Follow-up time longer than 3 months.

### Search strategy

The search strategy incorporated both electronic search and hand-search. The following electronic databases were utilised: (i) MEDLINE In-Process & Other Non-Indexed Citations and MEDLINE 1950 to present via Ovid interface; (ii) EMBASE Classic + EMBASE 1947 to present via Ovid interface; (iii) The Cochrane Central Register of Controlled Trials (CENTRAL); (iv) LILACS; and (v) Web of Science. The electronic search strategy included terms related to the intervention and used the following combination of keywords and MeSH terms: ("tooth extraction" OR "tooth removal" OR "socket" OR "alveol" OR "ridge" OR "crest" OR "tooth-socket" OR "alveolarbone loss" OR "boneresorption" OR "boneremodelling") AND ("preserve" OR "reconstruct" OR "augment" OR "fill" OR "seal" OR "graft" OR "repair" OR "alveolar ridge augmentation" OR "bone regeneration" OR "bone substitutes" OR "transplantation"). Cochrane search filters for RCTs and CCTs were implemented, with cohort trials also included. The results were limited to human studies. The full electronic search strategy can be found in the Appendix.

An extensive hand-search was also performed encompassing the bibliographies of the included papers and other narrative and systematic reviews. In addition, the following journals were screened from 2001 to July 2014: Clinical Oral Implants Research, Clinical Implant Dentistry and Related Research, European Journal of Oral Implantology, Implant Dentistry, International Journal of Oral and Maxillofacial Implants, International Journal of Periodontics and Restorative Dentistry, Journal of Clinical Periodontology, Journal of Dental Research, Journal of Oral and Maxillofacial Surgery, Journal of Periodontology, Oral Surgery, Oral Medicine, Oral Radiology, Oral Pathology and Endodontics. No language restrictions were applied, and translations were carried out if necessary. Unpublished trials and abstracts were not included in the search process. When the results of a study were presented in a number of publications, the most complete data set

was included in the analysis. In case of missing or incomplete data, the authors were contacted via email allowing a period of 3 weeks for their reply with the missing data. The extracted data were copied into EndNote X7 software (Thomson Reuters, New York, NY, USA), and all further steps of screening were performed on this interface. A three-stage selection of the resulted hits was performed independently and in duplicate by two reviewers (ATE and NDM). In order to reduce errors and bias, a calibration exercise was performed with the first 24 articles identified from the journal hand-search. In case of disagreement at the title selection stage, the trial was included in the abstract stage. At the abstract and full-text selection, any disagreements between the above reviewers were resolved by discussion including a third reviewer (NM). The reasons for exclusion were recorded in a specific data extraction form at the full-text selection stage. The level of agreement was determined by a kappa score calculation of agreement during the title and abstract selection process.

### Research synthesis and meta-analysis

For all included studies answering both focused questions, a descriptive synthesis was undertaken. The studies were classified according to research design and type of intervention and the outcomes were recorded in evidence tables.

For focused question 1, meta-analysis was conducted utilising the available data from the selected RCT and CCT studies. The analysis was undertaken separating the studies according to parallel and split-mouth designs and was only carried out if each group contained more than 2 eligible studies.

For focused question 2, meta-analysis was conducted utilising the available data from all the studies included in the analysis of focused question 1 and data from RCTs and CCTs with parallel design, as well as larger prospective case series. The studies included for meta-analysis were divided into three different groups (*GBR*, *socket grafting and socket seal*) with analysis only carried out if each group contained more than 2 eligible studies. When ARP was performed utilising a resorbable or non-resorbable barrier membrane, the study was categorised in the *GBR* group. This was independent of whether an additional bone grafting material was used. When the socket was treated with a bone or substitute graft, including collagen sponges/plaques and growth factors, the study was categorised in the *socket grafting* group. Finally, the study was categorised in the

socket seal group when a soft tissue graft was used to seal the entrance of the socket with or without grafting of the socket following a flapless approach.

MedCalc® version 15.11.0 (MedCalc Software bvba, Ostend, Belgium) software was used for the meta-analyses for focused question 1. For question 2, Comprehensive Meta Analysis version 3.3.070 (Biostat, Inc., Englewood, NJ, USA) software was used.

When several intervention groups were reported on, these were combined into one single intervention group, as advised in The Cochrane Handbook for Systematic Reviews of Interventions (Higgins & Green 2011).

Assessment of statistical heterogeneity was performed using Cochran's Q-test and determination of the  $I^2$  index (Higgins et al. 2003). The  $I^2$  index provides an estimate of the amount of variation attributable to heterogeneity ( $I^2 = 25\%$ : low;  $I^2 = 50\%$ : moderate;  $I^2 = 75\%$ : high heterogeneity). The different outcome variable estimates were pooled using a random effects model, as the effect of ARP was anticipated as varying between individual studies (Borenstein et al. 2009).

For questions 1 and 2, a standardised mean difference (i.e. the difference in means divided by the standard deviation) was calculated for continuous variables. For question 2, forest plots were created to illustrate the effects of the different studies, shown against the global estimate.

Statistical significance was achieved if  $P < 0.05$ . The unit of analysis used for the study was the patient. Results are given as mean  $\pm$  standard deviation (SD) unless stated differently.

## Results

### Study selection

The initial search yielded a total 14,409 records including 82 papers that were selected through hand-search and two more through cross-reference. After removal of duplicates and title and abstract screening, a total of 112 articles were left for full-text assessment (Fig. 1). The authors of 5 of these 112 articles were contacted at this stage to provide additional data on ARP dimensional outcomes before the final selection.

The most common reason for exclusion of papers was insufficient numbers of patient, no relevant outcome data, data which was relevant but recorded in a manner/format which was incompatible with the inclusion criteria, duplicate report, insufficient follow-up time and the study design not matching research protocol. The excluded papers and

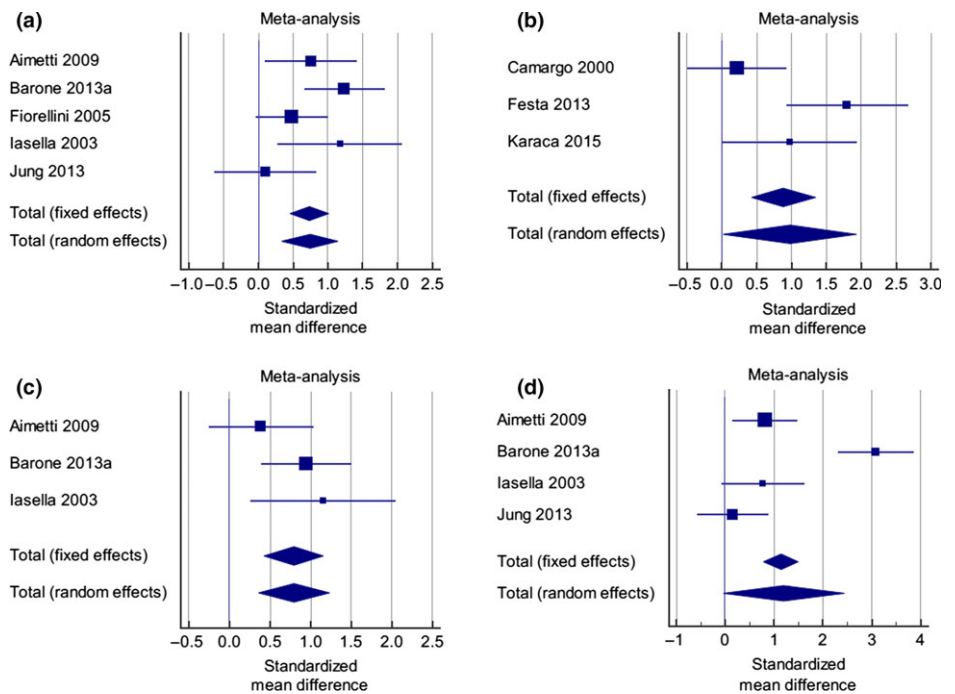


Fig. 1. Meta-analysis results and heterogeneity test for Q1; parallel studies, (a) Parallel studies investigating linear and volumetric changes in vertical alveolar bone height (Mid-Buccal). (b) Split mouth studies reporting on changes in the mid-buccal vertical alveolar ridge dimensions. (c) Parallel studies investigating linear and volumetric changes in vertical alveolar bone height (proximal). (d) Parallel studies investigating linear and volumetric changes in alveolar bone width.

the reasons for exclusion for both focused questions are listed in Table 1.

The kappa score for agreement between the reviewers (ATE and NDM) at the title and abstract selection level was 0.95, indicating a high level of agreement.

### Study design and population

The study design and study population characteristics of the included studies for both focused questions are presented in Table 2.

Controlled studies answering the focus question 1 Nine papers (Camargo et al. 2000; Iasella et al. 2003; Fiorellini et al. 2005; Aimetti et al. 2009; Barone et al. 2013a; Festa et al. 2013; Jung et al. 2013; Cardaropoli et al. 2014; Karaca et al. 2015) were eligible for inclusion in the qualitative analysis for focused question 1. Eight of the studies (Iasella et al. 2003; Fiorellini et al. 2005; Aimetti et al. 2009; Barone et al. 2013a; Festa et al. 2013; Jung et al. 2013; Cardaropoli et al. 2014; Karaca et al. 2015) were designed as RCT trials, with one (Camargo et al. 2000) a CCT. Six of the studies were of a parallel design (Iasella et al. 2003; Fiorellini et al. 2005; Aimetti et al. 2009; Barone et al. 2013a; Jung et al. 2013; Cardaropoli et al. 2014) and three studies (Camargo et al. 2000; Festa et al. 2013; Karaca et al. 2015) of a split-mouth design. Five of the studies

(Camargo et al. 2000; Fiorellini et al. 2005; Aimetti et al. 2009; Festa et al. 2013; Jung et al. 2013) performed ARP utilising socket grafting procedures, three studies used GBR (Iasella et al. 2003; Barone et al. 2013a; Cardaropoli et al. 2014), and one study used socket sealing (Karaca et al. 2015).

Follow-up after ARP ranged from 3 to 6 months. Two studies (Aimetti et al. 2009; Karaca et al. 2015) measured the dimensions of the post-extraction alveolar ridge at 3 months, three (Fiorellini et al. 2005; Barone et al. 2013a; Cardaropoli et al. 2014) at 4 months, one at 4 and 6 months (Iasella et al. 2003) and the remaining three (Camargo et al. 2000; Festa et al. 2013; Jung et al. 2013) at 6 months.

All of the included studies measured alveolar and gingival tissue site dimensions using direct intraoral measurements (Camargo et al. 2000; Iasella et al. 2003; Aimetti et al. 2009; Barone et al. 2013a; Festa et al. 2013; Cardaropoli et al. 2014) or radiographic CBCT analysis (Fiorellini et al. 2005, Jung et al. 2013; Karaca et al. 2015).

Eight (Camargo et al. 2000; Iasella et al. 2003; Fiorellini et al. 2005; Aimetti et al. 2009; Festa et al. 2013; Jung et al. 2013; Cardaropoli et al. 2014; Karaca et al. 2015) of the nine included studies prescribed pre- or post-operative antibiotics.

**Table 1.** List of excluded full-text papers and reasons for exclusion following full-text screening

Author and year	Reasons for exclusion
Alkan 2013	Insufficient number of patients
Al-Khalidi 2011	No relevant outcome data or data provided in incompatible format
Anitua 1999	Insufficient number of patients
Anitua 2015	No relevant outcome data or data provided in incompatible format, insufficient follow-up
Araujo 2015	No relevant outcome data or data provided in incompatible format
Artzi 2000	Insufficient number of patients
Babbush 2003	Insufficient number of patients
Barone 2008	Duplicate report (Barone 2012)
Barone 2012	No relevant outcome data or data provided in incompatible format
Brkovic 2012	Insufficient number of patients
Brownfield 2012	Insufficient number of patients
Canullo 2013	Insufficient number of patients
Canuto 2013	No relevant outcome data or data provided in incompatible format, insufficient follow-up
Cardaropoli 2012	Duplicate report (Cardaropoli 2014)
Carmagnola 2003	Insufficient number of patients
Casado 2010	Insufficient number of patients
Crespi 2009	No relevant outcome data or data provided in incompatible format
Clozza 2012	Duplicate report (Clozza 2014), insufficient number of patients
Clozza 2014	Insufficient number of patients
Collins 2014	Insufficient number of patients
De Coster 2011	Insufficient number of patients, study seems to be retrospective
Engler-Hamm 2011	Insufficient number of patients
Farina 2013	No relevant outcome data or data provided in incompatible format
Fotek 2009	Insufficient number of patients
Flugge 2015	Unclear study design
Geffre 2010	Animal study
Geurs 2014	Insufficient number of patients
Hanser 2014	Study seems to be retrospective
Hauser 2013	Insufficient number of patients
Heberer 2008	Insufficient number of patients
Heberer 2011	Insufficient number of patients
Heberer 2012	Insufficient number of patients
Hernández-Alfaro 2005	Insufficient number of patients, reports on a mixture of clinical situations (ARP, discrepancy implant socket, reconstruction after removal of implants, etc.)
Hsuan-Yu 2012	Insufficient number of patients
Irinakis 2006	Review article
Jung 2004	No relevant outcome data or data provided in incompatible format, insufficient follow-up
Kim 2011	No relevant outcome data or data provided in incompatible format
Kim 2013	Insufficient number of patients
Kotsakis 2014a	Insufficient number of patients
Kotsakis 2014b	Insufficient number of patients
Lambert 2012	Insufficient number of patients
Leblebicioglu 2013	No relevant outcome data or data provided in incompatible format
Lekovic 1998	Duplicate report (Camargo et al. 2000)
Lucyszyn 2005	Insufficient number of patients
Madan 2014	Insufficient number of patients
Mahesh 2012	Study design
Mardas 2011	Duplicate report (Mardas et al. 2010)
Mardinger 2009	Duplicate report (Mardinger et al. 2012)
Misch 2010	Insufficient number of patients
Moghaddas 2012	Insufficient number of patients
Nam 2011	No relevant outcome data or data provided in incompatible format
Neiva 2011	Insufficient number of patients
Ntounis 2015	Insufficient follow-up
Nevins 2014	Insufficient number of patients
Norton 2002	Insufficient number of patients
Oghli 2010	No relevant outcome data or data provided in incompatible format
Patel 2013	Duplicate (Mardas et al. 2010)
Pellegrini 2014	Insufficient number of patients
Ruga 2011	Insufficient number of patients
Scheyer 2012	Insufficient number of patients
Schneider 2014	Duplicate report (Jung et al. 2013)
Serino 2008	Insufficient number of patients

Five parallel studies (Iasella et al. 2003; Fiorellini et al. 2005; Aimetti et al. 2009; Barone et al. 2013a; Jung et al. 2013) were included in the meta-analysis. Cardaropoli et al. (2014) was excluded from the meta-analysis as the study used the socket as the unit of analysis, preventing pooling of data. A separate meta-analysis was carried out for the split-mouth studies undertaken by Festa et al. (2013), Camargo et al. (2000); Karaca et al. (2015).

The study population ranged from 15 to 80 patients in the included studies. This resulted in 194 patients being considered in the meta-analysis. One hundred and fifty-three patients were present in parallel studies and 41 in the split-mouth studies. The distribution of the extracted teeth included both single- and multi-rooted teeth. Two of the studies included smokers (Barone et al. 2013a; Jung et al. 2013), two studies (Aimetti et al. 2009; Festa et al. 2013) excluded smokers and four (Camargo et al. 2000; Fiorellini et al. 2005; Iasella et al. 2003; Karaca et al. 2015) did not report on smoking habits.

Studies answering the focus question 2

Thirty-seven studies (Camargo et al. 2000; Iasella et al. 2003; Serino et al. 2003; Vance et al. 2004; Fiorellini et al. 2005; Pinho et al. 2006; Neiva et al. 2008; Aimetti et al. 2009; Crespi et al. 2009, 2011a,b; Beck & Mealey 2015; Borg and Mealey 2010; Mardas et al. 2010; Fernandes et al. 2011; Huh et al. 2011; Gholami et al. 2012; Hoang & Mealey 2012; Mardinger et al. 2012; Perelman-Karmon et al. 2012; Wood & Mealey 2012; Barone et al. 2013a,b, 2014; Cook & Mealey 2013; Festa et al. 2013; Jung et al. 2013; Poulidas et al. 2013; Wallace et al. 2013; Calasans-Maia et al. 2014; Cardaropoli et al. 2014; Coomes et al. 2014; Eskow & Mealey 2014; Kim et al. 2014; Lindhe et al. 2014; Karaca et al. 2015; Meloni et al. 2015) were included in the qualitative analysis of question 2. Twenty-nine studies (Iasella et al. 2003; Vance et al. 2004; Fiorellini et al. 2005; Pinho et al. 2006; Neiva et al. 2008; Aimetti et al. 2009; Borg and Mealey 2010; Mardas et al. 2010; Crespi et al. 2011b; Fernandes et al. 2011; Huh et al. 2011; Gholami et al. 2012; Hoang & Mealey 2012; Perelman-Karmon et al. 2012; Wood & Mealey 2012; Barone et al. 2013a,b, 2014; Cook & Mealey 2013; Festa et al. 2013; Jung et al. 2013; Poulidas et al. 2013; Calasans-Maia et al. 2014; Cardaropoli et al. 2014; Coomes et al. 2014; Eskow & Mealey 2014; Kim et al. 2014; Karaca et al. 2015; Meloni et al. 2015) were

Table 1. (continued)

Author and year	Reasons for exclusion
Simon 2011	No relevant outcome data or data provided in incompatible format
Sisti 2012	Insufficient follow-up
Shakibaie 2013	Insufficient number of patients
Spinato 2014	No relevant outcome data or data provided in incompatible format
Suttapreyasri 2013	Insufficient number of patients
Tal 1999	Unclear study design and insufficient follow-up
Tete 2013	Reports on a mixture of clinical situations (ARP vs. sinus augmentation), insufficient follow-up
Thalmair 2013	Insufficient number of patients
Toloue 2012	Unclear study design
Vanhoutte 2014	Duplicate report (Lambert 2012)
Villanueva-Alcojol 2013	Insufficient number of patients
Weiss 2007	Insufficient number of patients
Wu 2014	Insufficient number of patients

designed as a RCT, seven studies (Camargo et al. 2000; Serino et al. 2003; Crespi et al. 2009, 2011a; Beck & Mealey 2010; Wallace et al. 2013; Lindhe et al. 2014) designed as a CCT and one study (Mardinger et al. 2012) was a prospective case series.

Eleven studies (Fiorellini et al. 2005; Neiva et al. 2008; Beck & Mealey 2010; Crespi et al. 2011a; Huh et al. 2011; Hoang & Mealey 2012; Wood & Mealey 2012; Jung et al. 2013; Calasans-Maia et al. 2014; Coomes et al. 2014 and Eskow & Mealey 2014) compared two different grafting techniques with seven studies (Iasella et al. 2003; Serino et al. 2003; Aimetti et al. 2009; Crespi et al. 2009, 2011b; Festa et al. 2013; Cardaropoli et al. 2014) comparing a grafting procedure with unassisted socket healing. One study (Barone et al. 2013a) compared GBR with unassisted socket healing, twelve studies (Pinho et al. 2006; Mardas et al. 2010; Fernandes et al. 2011; Gholami et al. 2012; Perelman-Karmon et al. 2012; Barone et al. 2013b, 2014; Cook & Mealey 2013; Poulias et al. 2013; Wallace et al. 2013; Kim et al. 2014; Borg & Mealey 2015) compared different GBR techniques. Four studies (Mardinger et al. 2012; Lindhe et al. 2014; Karaca et al. 2015; Meloni et al. 2015) compared different socket seal techniques, and one study (Vance et al. 2004) compared a grafting procedure against GBR. Finally, 3 studies (Fiorellini et al. 2005; Crespi et al. 2009; Jung et al. 2013) compared multiple grafting techniques against an unassisted healing control.

Follow-up times ranged from 3 to 9 months after the ARP. Seven studies (Neiva et al. 2008; Aimetti et al. 2009; Crespi et al. 2009; Huh et al. 2011; Barone et al. 2014; Kim et al. 2014; Karaca et al. 2015) examined dimensions after 3 months of healing, 16 studies after 4–6 months (Iasella et al. 2003; Poulias et al. 2013; Vance et al. 2004; Fiorellini et al. 2005; Beck & Mealey 2010;

Crespi et al. 2011a,b; Wood & Mealey 2012; Barone et al. 2013a; Cook & Mealey 2013; Wallace et al. 2013; Cardaropoli et al. 2014; Coomes et al. 2014; Eskow & Mealey 2014; Borg & Mealey 2015; Meloni et al. 2015), 13 studies after 6–9 months (Camargo et al. 2000; Serino et al. 2003; Pinho et al. 2006; Mardas et al. 2010; Fernandes et al. 2011; Gholami et al. 2012; Hoang & Mealey 2012; Mardinger et al. 2012; Barone et al. 2013b; Festa et al. 2013; Jung et al. 2013; Calasans-Maia et al. 2014; Lindhe et al. 2014) and one study after 9 months (Perelman-Karmon et al. 2012).

Twenty-eight of the studies measured alterations in site dimensions. Twenty-two (Camargo et al. 2000; Iasella et al. 2003; Serino et al. 2003; Vance et al. 2004; Pinho et al. 2006; Neiva et al. 2008; Aimetti et al. 2009; Beck & Mealey 2010; Borg and Mealey 2010; Mardas et al. 2010; Fernandes et al. 2011; Gholami et al. 2012; Hoang & Mealey 2012; Wood & Mealey 2012; Barone et al. 2013a, 2014; Cook & Mealey 2013; Festa et al. 2013; Poulias et al. 2013; Calasans-Maia et al. 2014; Cardaropoli et al. 2014; Eskow & Mealey 2014; Karaca et al. 2015) directly measured the alteration in the size of alveolar complex, with seven studies recording measurements from intraoral (Crespi et al. 2009) or CBCT (Fiorellini et al. 2005; Huh et al. 2011; Jung et al. 2013; Kim et al. 2014; Karaca et al. 2015; Meloni et al. 2015) radiographic images. One study measured both intraoral and radiographic measurements (Coomes et al. 2014). Seven studies (Crespi et al. 2011a,b; Mardinger et al. 2012; Perelman-Karmon et al. 2012; Barone et al. 2013b; Wallace et al. 2013; Lindhe et al. 2014) did not attempt to measure dimensional changes of the hard tissues but provided either histological information or soft tissue changes.

Twenty-nine (Camargo et al. 2000; Iasella et al. 2003; Vance et al. 2004; Pinho et al.

2006; Neiva et al. 2008; Aimetti et al. 2009; Crespi et al. 2009, 2011a,b; Beck & Mealey 2010; Mardas et al. 2010; Fernandes et al. 2011; Gholami et al. 2012; Hoang & Mealey 2012; Mardinger et al. 2012; Wood & Mealey 2012; Cook & Mealey 2013; Festa et al. 2013; Jung et al. 2013; Barone et al. 2014; Calasans-Maia et al. 2014; Cardaropoli et al. 2014; Coomes et al. 2014; Eskow & Mealey 2014; Kim et al. 2014; Lindhe et al. 2014; Borg & Mealey 2015; Karaca et al. 2015) of the 37 included studies prescribed pre- or post-operative antibiotics. Four studies (Perelman-Karmon et al. 2012; Barone et al. 2013a; Poulias et al. 2013 – one group and Serino et al. 2003) did not prescribe AB as a component of treatment, and five studies (Neiva et al. 2008; Huh et al. 2011; Barone et al. 2013b; Poulias et al. 2013 – one group and Wallace et al. 2013) did not provide this information.

Eighteen studies were included in the meta-analysis (Iasella et al. 2003; Vance et al. 2004; Fiorellini et al. 2005; Neiva et al. 2008; Aimetti et al. 2009; Mardas et al. 2010; Huh et al. 2011; Hoang & Mealey 2012; Wood & Mealey 2012; Barone et al. 2013a, 2014; Jung et al. 2013; Poulias et al. 2013; Calasans-Maia et al. 2014; Coomes et al. 2014; Kim et al. 2014; Borg & Mealey 2015; Meloni et al. 2015). The study population ranged from 20 to 80 patients. Following categorisation into intervention groups, 266 patients were considered for the meta-analysis of the GBR group, 317 patients for the meta-analysis of the *socket grafting* group and 50 patients for the meta-analysis of the socket seal group. Although the distribution of the teeth extracted in the GBR and *socket grafting* groups was fairly heterogeneous and included both single- and multi-rooted teeth, the location of the extracted teeth in the *socket seal* group was mainly maxillary, non-molar teeth.

Seven of the studies included both smokers and non-smokers (Mardas et al. 2010; Barone et al. 2013a, 2014; Jung et al. 2013; Poulias et al. 2013; Coomes et al. 2014; Meloni et al. 2015), six (Iasella et al. 2003; Vance et al. 2004; Fiorellini et al. 2005; Huh et al. 2011; Hoang & Mealey 2012; Kim et al. 2014) did not report on smoking habits, and five studies (Neiva et al. 2008; Aimetti et al. 2009; Wood and Mealey 2012; Calasans-Maia et al. 2014; Borg & Mealey 2015) excluded smokers.

#### Intervention characteristics

The interventional characteristics of the included studies for both focused questions are presented in Table 2.

Controlled studies answering the focused question 1 In four of the nine included studies (Camargo et al. 2000; Iasella et al. 2003; Fiorellini et al. 2005; Festa et al. 2013), mucoperiosteal flaps were elevated at both the ARP-treated and control extraction sites. In one paper (Cardaropoli et al. 2014), a flap was only raised in the treatment group. In the remaining four studies (Aimetti et al. 2009; Barone et al. 2013a,b; Jung et al. 2013; Karaca et al. 2015), a flapless approach was followed. Primary closure was attempted in both the treatment and control groups in one study (Fiorellini et al. 2005), with one study (Jung et al. 2013) undertaking primary closure in two of three treatment groups and one study (Festa et al. 2013) only in the control group. In the five studies that specified the number of intact walls at the extraction site, all had at least 3 walls intact after extraction of the tooth (Fiorellini et al. 2005; Aimetti et al. 2009; Festa et al. 2013; Jung et al. 2013; Cardaropoli et al. 2014).

In three of the nine included studies, ARP was performed using a collagen barrier for GBR in combination with a porcine xenograft (Barone et al. 2013a; Cardaropoli et al. 2014) or an allograft (Iasella et al. 2003). In three studies, socket grafting was undertaken using an alloplast material, with calcium sulphate or calcium phosphate (Aimetti et al. 2009; Jung et al. 2013) and bioactive glass (Camargo et al. 2000) utilised. In one study, a porcine xenograft with a porcine cortical layer was used for grafting of the sockets (Festa et al. 2013), and in another study, a polylactide-polyglycolide acid sponge and human BMP was provided (Fiorellini et al. 2005). Two socket seal techniques were examined against a socket grafting technique in one study (Jung et al. 2013), with the effects of a porcine collagen matrix seal compared against a connective tissue graft. One study (Karaca et al. 2015) examined the effects of socket sealing using a free gingival graft.

Studies answering the focused question 2

#### GBR

In seven of the ten included studies (Iasella et al. 2003; Vance et al. 2004; Pinho et al. 2006; Mardas et al. 2010; Fernandes et al. 2011; Poulias et al. 2013; Kim et al. 2014; Borg & Mealey 2015), mucoperiosteal flaps were elevated as a component of the surgery. Two studies adopted a flapless surgical technique (Barone et al. 2013a, 2014 – one group). Pinho et al. (2006) and Barone et al. (2014 – one group) attempted primary closure at the

tooth extraction site following GBR augmentation.

In the four studies that specified the number of intact walls required for inclusion in the study, all had at least 3 walls of the socket walls remaining intact, with greater than 50% of the 4th wall remaining after extraction of the tooth (Mardas et al. 2010; Barone et al. 2014; Kim et al. 2014; Borg & Mealey 2015).

GBR was performed in most of the studies using a collagen barrier in combination with either a porcine or bovine xenograft (Barone et al. 2013a, 2014; Mardas et al. 2010 – one group and Vance et al. 2004), hydroxyapatite (Cook & Mealey 2013 – one group, Gholami et al. 2012 – one group), synthetic ceramic (Mardas et al. 2010 – one group) or freeze-dried bone allograft (-PTFE membrane, Iasella et al. 2003; Vance et al. 2004 – one group; Poulias et al. 2013; Kim et al. 2014; Borg & Mealey 2015). One study (Pinho et al. 2006) used an autograft harvested from the maxillary tuberosity in combination with a titanium barrier. An acellular dermal matrix barrier in combination with an acellular dermal matrix allograft was used by Fernandes et al. (2011), and a resorbable polylactide barrier with cancellous allograft with or without bovine xenograft was used by Poulias et al. (2013).

#### Socket grafting

In five of the twelve included studies (Camargo et al. 2000; Vance et al. 2004; Fiorellini et al. 2005; Festa et al. 2013; Calasans-Maia et al. 2014), mucoperiosteal flaps were elevated as a component of the surgery. Four studies adopted a flapless surgical technique (Neiva et al. 2008; Aimetti et al. 2009; Jung et al. 2013; Coomes et al. 2014). It was unclear whether flaps were elevated in three studies (Huh et al. 2011; Hoang & Mealey 2012; Wood & Mealey 2012). Primary tissue closure was attempted in four of the studies (Calasans-Maia et al. 2014; Fiorellini et al. 2005; Jung et al. 2013 – two groups and Festa et al. 2013 – one group), with only one group in one study not specifying the surgical technique (Huh et al. 2011). All other groups did not attempt primary closure.

In the eight studies that specified the number of intact walls required for inclusion in the study, all required at least 3 walls of the socket wall remaining intact, with greater than 50% of the fourth wall remaining after extraction of the tooth (Fiorellini et al. 2005; Neiva et al. 2008; Aimetti et al. 2009; Hoang & Mealey 2012; Festa et al. 2013; Jung et al. 2013; Coomes et al. 2014).

Socket grafting was performed using either allografts (Calasans-Maia et al. 2014), xenografts (Vance et al. 2004 – one group; Festa et al. 2013), xenografts combined with a synthetic collagen peptide collagen known as P-15 (Neiva et al. 2008 – one group), alloplasts and bioactive glass materials (Camargo et al. 2000; Aimetti et al. 2009; Jung et al. 2013 – one group), a combination of alloplasts, xenografts and rhBMP-2 (Huh et al. 2011), a combination of allograft and collagen (Wood & Mealey 2012), a combination of synthetic polymer, ceramic material and allograft (Vance et al. 2004 – one group), a demineralised xenograft matrix in bovine collagen and sodium alginate carrier (Hoang & Mealey 2012) and a collagen carrier with and without rhBMP-2 (Fiorellini et al. 2005; Coomes et al. 2014).

#### Socket seal

All three included studies (Jung et al. 2013; Karaca et al. 2015; Meloni et al. 2015) adopted a flapless surgical technique. Two of these studies required patients to have at least 3 walls of the socket walls intact, with the fourth wall having greater than 50% of the buccal bone remaining or a dehiscence or fenestration of <3 mm. No description of the socket wall morphology was provided by Karaca et al. (2015).

Both Meloni et al. (2015), Jung et al. (2013) examined the effects of socket sealing using a bone allograft and either a connective tissue (Meloni et al. 2015) or free gingival graft (Jung et al. 2013) in comparison with ARP using an allograft and porcine collagen matrix. The allograft in the Jung et al. (2013) study was a deproteinised bovine bone mineral with 10% collagen. Karaca et al. (2015) examined the isolated effect of using a free gingival graft for socket sealing.

#### Outcome variables

The outcomes for the collected data for both focused questions 1 and 2 are presented in Table 3.

Outcome of controlled studies answering focused question 1

#### *Linear and volumetric changes in vertical alveolar bone height (mid-buccal)*

*Parallel studies:* Five studies (Fig. 2) reported on changes in the mid-buccal vertical alveolar ridge height dimensions (Iasella et al. 2003; Aimetti et al. 2009; Barone et al. 2013a; Jung et al. 2013; Cardaropoli et al. 2014). There was a moderate level of heterogeneity ( $I^2 = 55.33\%$ ,  $P = 0.0839$ ). The standardised

**Table 2. Study characteristics of included papers**

References	Setting (country, number, type centre)	Source of funding, reported conflict of interest	Study design	Who carried out procedures	Number of patients (sockets)	Mean age $\pm$ SD and/or range	Smokers included	Socket location and defect morphology
Aimetti et al. (2009)* <sup>†</sup>	Italy, 1, U	Unclear	RCT, Parallel	Unclear	40 (40)	51.27 $\pm$ 8.40; 36–68	N	Anterior maxillary single-tooth; 4 walls
Barone et al. (2013a)* <sup>†</sup>	Italy, 1, H	Unclear	RCT, Parallel	Specialists	58 (58)	40.5; 20–63	Y	Molar or premolar
Barone et al. (2013b) <sup>‡</sup>	Italy, Germany, Spain, 6, U and P?	Industry, Unclear	RCT, Unclear	Unclear	38 (62)	51 $\pm$ 14	Y	Molar or premolar; excluded if facial soft tissue and buccal plate markedly reduced
Barone et al. (2014) <sup>†</sup>	Italy, 1, H	Unclear, No	RCT, Parallel	Specialists	64 (64)	32.7 $\pm$ 12.4; 18–47	Y	Molar or premolar; 4 walls
Beck and Mealey (2010)	USA, 1, U	Self-funded, Yes	CCT, Parallel	Unclear	33 (38)	57.4; 39–76	?	Single root; excluded if >50% of any socket wall absent
Borg and Mealey (2015) <sup>†</sup>	USA, Unclear, Unclear	Industry, Yes	RCT, Parallel	Specialists	42 (42)	52; 20–89	N	Single-rooted tooth; excluded if >50% dehiscence
Calasans-Maia et al. (2014) <sup>†</sup>	Brazil, 1, U	Unclear	RCT, Parallel	Unclear	20 (20)	44.55 $\pm$ 10.87; 23–60	N	Unclear
Camargo et al. (2000)*	Unclear	Industry, Unclear	CCT, Split-mouth	Unclear	16 (32)	44 $\pm$ 15.9	?	Non-molar
Cardaropoli et al. (2014)	Italy, 1, P	Unclear	RCT, Parallel	Unclear	41 (48)	47.2 $\pm$ 12.9	Y	Molar or premolar; 3 intact walls and at least 80% of fourth wall intact
Cook and Mealey (2013)	USA, 1, U	Industry, No	RCT, Parallel	Specialist trainees	38 (40)	56; 23–78	Y	Non-molar; excluded if bony dehiscence >50% of total socket depth
Coomes et al. (2014) <sup>†</sup>	USA, 1, U	Industry, Yes	RCT, Parallel	Unclear	34 (34)	19–79	Y	Buccal bone destruction
Crespi et al. (2009a) <sup>‡</sup>	Italy, 1, H	Unclear, No	CCT, Split-mouth	Specialists	15 (45)	51.3; 28–72	N	Molar or premolar; 3 bone walls and loss of buccal plate
Crespi et al. (2011a) <sup>‡</sup>	Italy, 1, H	Unclear	CCT, Split-mouth	Specialists	15 (45)	53.7; 32–70	N	One molar or premolar on each side of jaw and one additional randomly located tooth to be used as a control
Crespi et al. (2011b) <sup>‡</sup>	Italy, 1, H	Unclear	RCT, Split-mouth	Specialists	15 (30)	53.7; 32–70	N	One molar or premolar on each side of jaw; 3 bone walls and loss of buccal plate
Eskow & Mealey (2014) <sup>‡</sup>	USA, 1?, U	Unclear, No	RCT, Parallel	Unclear	35 (35)	54; 27–79	Y	Non-molar; excluded if >50% of socket wall's vertical dimension absent
Fernandes et al. (2011)	Brazil, 1, U	Unclear, No	RCT, Split-mouth	Unclear	18 (36)	33–58	?	Maxillary single-rooted teeth
Festa et al. (2013)*	Italy, 1, U	Unclear, No	RCT, Split-mouth	Unclear	15 (30)	28–58	N	Premolars; excluded if buccal or palatal/lingual bony wall fractured/lost
Fiorellini et al. (2005)* <sup>†</sup>	USA?, 8, U	Industry, Yes	RCT, Parallel	Unclear	80 (95)	47.4	?	Non-molar maxillary teeth; buccal wall defects
Gholami et al. (2012)	Iran, 1?, U?	Unclear	RCT, Split-mouth	Unclear	12 (28)	44.6 $\pm$ 11.4; 21–60	?	Non-molar; four-wall sockets
Hoang & Mealey (2012) <sup>†</sup>	USA, 1, U	Self-funded, No	RCT, Parallel	Unclear	30 (30)	56.1; 29–76	?	Molar; excluded if buccal bony dehiscence >50% of length of socket



Materials (details, number of patients/sockets)	Atraumatic extraction	Flap raised	Primary closure	Pre- or post-operative antibiotics	Healing time before measurement/ biopsy	Dimensions of ridge evaluated by
Grafting (CS; 22/22) vs. unassisted healing (18/18)	Y	N	N	Y	3	Directly
GBR (corticocancellous porcine bone + collagen barrier; 29/29) vs. unassisted healing (29/29)	?	N	N	N	4	Directly
GBR (bovine xenograft + collagen barrier; ?/31; T1) vs. GBR (bovine xenograft + collagen barrier; ?/31; T2)	Y	Y	N	?	6	-
GBR (corticocancellous porcine bone + collagen barrier; 32/32; T1) vs. GBR (corticocancellous porcine bone + collagen barrier; 32/32; T2)	Y	T1: N T2: Y	T1: N T2: Y	Y	3	Directly
Grafting (non-freeze-dried cancellous mineralised human bone allograft + collagen; 19/22; T1) vs. grafting (non-freeze-dried cancellous mineralised human bone allograft + collagen; 14/16; T2)	Y	N	N	Y	Approx 2.5 or approx 5.5	Directly
GBR (cortical mineralised FDBA + d-PTFE barrier; 20/20; T1) vs. GBR (70% cortical mineralised FDBA/30% cortical DFDBA + d-PTFE barrier; 21/21; T2)	Y	Y	N	Y	17–21 weeks (average 19 weeks)	Directly
Grafting (DBBM; 10/10; T1) vs. grafting (DBBM; 10/10; T2)	Y	Y	Y	Y	6	Directly
Grafting (bioactive glass + CS; 16/16) vs. unassisted healing (16/16)	Y	Y	N	Y	6	Directly
GBR (bovine bone mineral blended with collagen + collagen barrier; 21/24) vs. unassisted healing (20/24)	Y	T1: Y C: N	N	Y	4	Directly
GBR (bovine bone mineral blended with collagen + collagen barrier; 20/21; T1) vs. GBR (hydroxyapatite + collagen barrier; 18/19; T2)	Y	Y	N	Y	4–5	Directly
Grafting (collagen + rhBMP-2; 18/18; T1) vs. grafting (collagen; 16/16; T2)	Y	N	N	Y	5	Both
Grafting (MHA + collagen; 15/15; T1) vs. grafting (CS + collagen; 15/15; T2) vs. unassisted healing (15/15)	?	N	N	Y	3	Other
Grafting (MHA + collagen; 15/15; T1) vs. grafting (corticocancellous xenogenic bone + collagen; 15/15; T2) vs. grafting (collagen; 15/15; T3)	Y	N	N	Y	4	-
Grafting (corticocancellous xenogenic bone + collagen; 15/15) vs. unassisted healing (15/15)	?	T1: ? C: N	T1: N C: ?	Y	4	-
Grafting (cortical FDBA + collagen; 17/17; T1) vs. grafting (cancellous FDBA + collagen; 18/18; T2)	Y	N	N	Y	Approx. 4	Directly
GBR (anorganic bovine bone matrix with cell-binding peptide P-15 + acellular dermal matrix barrier; 18/18; T1) vs. GBR (acellular dermal matrix barrier; 18/18; T2)	Y	Y	N	Y	6	Directly
Grafting (corticocancellous porcine bone + soft cortical membrane; 15/15) vs. unassisted healing (15/15)	Y	Y	T1: N C: Y	Y	6	Directly
Grafting (collagen sponge with human BMP-2; 22/?; T1) vs. grafting (collagen sponge with BMP-2; 21/?; T2) vs. grafting (collagen sponge; 17/?; T3) vs. unassisted healing (20/?)	?	Y	Y	Y	4	CBCT
GBR (DBBM + collagen barrier; 12/14; T1) vs. GBR (nanocrystalline HA embedded in silica gel matrix + collagen barrier; 12/14; T2)	Y	Y	Y	Y	6–8	Directly
Grafting (demineralised bone matrix in a carrier of bovine collagen and sodium alginate + collagen; 16/16; T1) vs. grafting (demineralised bone matrix in a carrier of bovine collagen and sodium alginate + collagen; 14/14; T2)	Y	?	N	Y	4–5	Directly

Table 2. (continued)

References	Setting (country, number, type centre)	Source of funding, reported conflict of interest	Study design	Who carried out procedures	Number of patients (sockets)	Mean age $\pm$ SD and/or range	Smokers included	Socket location and defect morphology
Huh et al. (2011) <sup>†</sup>	South Korea, 3, Unclear	Governmental, Unclear	RCT, Parallel	Unclear	72 (72?)	52.77 $\pm$ 6.71; 35–65	?	Premolar or molar; <50% localised alveolar vertical bone loss
Iasella et al. (2003) <sup>*†</sup>	Unclear	Unclear	RCT, Parallel	Unclear	24 (24)	51.5; 28–76	?	Non-molar
Jung et al. (2013) <sup>*</sup>	Switzerland, 2 centres in 1 U	Institutional and industry, No	RCT, Parallel	Unclear	40 (40)	Per groups: 48 $\pm$ 15; 59 $\pm$ 11; 65 $\pm$ 13; 49 $\pm$ 14	Y	Excluded if >50% buccal bone height lost
Karaca et al. (2015) <sup>*</sup>	Turkey, 2?, U?	Self-funded	RCT, Split-mouth	Unclear	10 (20)	46.7; 36–60	?	Maxillary anterior teeth
Kim et al. (2014) <sup>†</sup>	South Korea, 2, U	Institutional, Unclear	RCT, Parallel	Unclear	59 (59)	Control 51.18 $\pm$ 10.14; experimental 50.37 $\pm$ 13.45	?	Non-molar; <50% bone loss in all dimensions.
Lindhe et al. (2014) <sup>‡</sup>	Unclear	Unclear	CCT, Parallel	Unclear	24 (24)	25–54	?	Excluded if buccal dehiscence defect $\geq$ 2 mm
Mardinger et al. (2012) <sup>‡</sup>	Israel, Unclear, U and P	Unclear	Prospective case series, Non-controlled	Unclear	36 (43)	50.75; 24–75	Y	Site not completely surrounded by bony walls; excluded if less than two bony wall defects
Meloni et al. (2015);	Italy, 2, P	Unclear, No	RCT, Parallel	Specialists	30 (30)	48; 26–72	Y	Maxillary non-molar; excluded if fenestration or dehiscence $\geq$ 3 mm
Neiva et al. (2008) <sup>†</sup>	USA, 1, U	Industry, No	RCT, Parallel	Specialists	24 (24)	25–76	N	Maxillary premolars with >80% bone volume in all dimensions
Patel (2013) <sup>†</sup>	United Kingdom, 1, U	Industry, Unclear	RCT, Parallel	Specialists	26 (26)	37.3 $\pm$ 11.4; 20–58	Y	Non-molar; excluded if major part of buccal or palatal wall damaged or lost
Perelman-Karmon et al. (2012) <sup>‡</sup>	Unclear	Unclear	RCT, Parallel	Unclear	23 (23)	26–68	N	Non-molar; at least 50% of sockets partially resorbed/destroyed at one to two walls, but not circumferentially
Pinho et al. (2006)	Brazil, 1, U	Unclear, No	RCT, Split-mouth	Unclear	10 (20)	46.3; 35–60	N	Maxillary non-molar
Poulias et al. (2013) <sup>†</sup>	USA, 1, U	Self-funded, No	RCT, Parallel	Specialist trainees	23 (23)	52 $\pm$ 16; 26–77	Y	Non-molar
Serino et al. (2003) <sup>‡</sup>	Unclear	Unclear	CCT, Unclear	Unclear	36 (39)	35–64	?	Unclear
Vance et al. (2004) <sup>†</sup>	Unclear	Industry, Unclear	RCT, Parallel	Unclear	24 (24)	56	?	Non-molar
Wallace et al. (2013) <sup>‡</sup>	Unclear	Industry, Yes	CCT, Parallel	Unclear	30 (34)	18–70	N	18 intact and 16 sockets with buccal wall defects
Wood and Mealey (2012) <sup>†</sup>	USA, 1, U	Industry, No	RCT, Parallel	Specialist trainees	33 (33)	56.7; 20–78	N	Single-rooted non-molar

U, university; H, hospital, P, private practice; Y, yes; N, no; ?, unclear; RCT, randomised clinical trial; CCT, controlled clinical trial; GBR, guided bone regeneration; T1, test group 1; T2, test group 2; T3, test group 3; C, control group; MHA, magnesium-enriched hydroxyapatite; CS, calcium sulphate; FDDBA, freeze-dried bone allograft; DBBM, deproteinised bovine bone mineral; HA, hydroxyapatite; DFDBA, demineralised freeze-dried bone allograft; d-PTFE, dense polytetrafluoroethylene;  $\beta$ -TCP, Beta-tricalcium phosphate.

All studies included for question 2; highlighted studies included for question 1.

\*Selected for meta-analysis question 1.

<sup>†</sup>Selected for meta-analysis question 2.

<sup>‡</sup>Included only for histological data.

Materials (details, number of patients/sockets)	Atraumatic extraction	Flap raised	Primary closure	Pre- or post-operative antibiotics	Healing time before measurement/ biopsy	Dimensions of ridge evaluated by
Grafting ( $\beta$ -TCP/HA + ErhBMP-2; 36/?; T1) vs. grafting ( $\beta$ -TCP/HA; 36/?; T2)	?	?	?	?	3	CBCT
GBR (FDDBA + collagen barrier; 12/12) vs. unassisted healing (12/12)	Y	Y	N	Y	4 or 6	Directly
Grafting ( $\beta$ -TCP particles with poly(lactide co-glycolide) coating; 10/10; T1) vs. sealing (DBBM with 10% collagen + porcine collagen matrix (Mucograft); 10/10; T2) vs. sealing (DBBM with 10% collagen + autogenous soft tissue graft; 10/10; T3) vs. unassisted healing (10/10)	Y	?	T1: N T2: Y T3: Y C: N	Y	6	CBCT
Sealing (free gingival graft from palate; 10/10) vs. unassisted healing (10/10)	Y	N	T: Y C: N	Y	3	CBCT
GBR (demineralised human bone matrix + rhBMP-2 + collagen barrier; 29/29; T1) vs. GBR (demineralised human bone matrix + rhBMP-2 + collagen barrier; 30/30; T2)	Y	Y	?	Y	3	CBCT
Sealing (DBBM + Mucograft; 13/13; T1) vs. sealing (Mucograft; 11/11; T2)	Y	N	Y	?	6	–
Sealing (porous bovine xenograft + intrasocket reactive soft tissue; 36/43)	Y	N	Y	Y	6	–
Sealing (DBBM + epithelial connective tissue graft from palate; 15/15; T1) vs. sealing (DBBM + porcine collagen matrix; 15/15; T2)	Y	N	Y	Y	5	CBCT
Grafting (anorganic bovine-derived HA matrix combined with a synthetic cell-binding peptide P-15 + collagen; 12/12; T1) vs. grafting (collagen; 12/12; T2)	Y	N	N	?	3.7	Directly
GBR (60% HA + 40% b-tricalcium phosphate + collagen barrier; 13/13; T1) vs. GBR (DBBM + collagen barrier; 13/13; T2)	Y	Y	N	Y	8	Directly
GBR (bovine bone mineral + collagen barrier; 11/11; T1) vs. grafting (bovine mineral bone; 12/12; T2)	?	Y	Y	N	9	–
GBR (autograft + titanium barrier; 10/10; T1) vs. GBR (titanium barrier; 10/10; T2)	Y	Y	Y	Y	6	Directly
GBR (cancellous allograft + resorbable polylactide barrier; 12/12; T1) vs. GBR (cancellous allograft + bovine xenograft + resorbable polylactide barrier; 11/11; T2)	Y	Y	N	T1: N T2: ?	4	Directly
Grafting (polylactide–polyglycolide acid sponge; 24/26) vs. unassisted healing (12/13)	?	Y	?	N	6	Directly
Grafting (carboxymethylcellulose + CS + DFDBA; 12/12; T1) vs. GBR (bovine bone mineral + collagen barrier; 12/12; T2)	Y	Y	N	Y	4	Directly
GBR (allograft + rhPDGF-BB + resorbable acellular dermal matrix barrier; ?/19; T1) vs. GBR (allograft + saline + acellular dermal matrix barrier; ?/15; T2)	Y	Y	Y	?	4	–
Grafting (DFDBA + collagen; 17/17; T1) vs. grafting (FDDBA + collagen; 16/16; T2)	Y	?	N	Y	4–4.7	Directly

**Table 3. Study outcomes of included papers (I)**

References	Comparison	Changes in vertical alveolar ridge dimensions – mid-buccal	Changes in vertical alveolar ridge dimensions – proximal	Changes in horizontal alveolar ridge dimensions	Histology (%)	Changes in keratinised tissues dimensions
Aimetti et al. (2009)*†	Grafting vs. unassisted healing	T $-0.5 \pm 1.1$ C $-1.2 \pm 0.6$	T $-0.2 \pm 0.6$ C $-0.5 \pm 0.9$	T $-2 \pm 1.1$ C $-3.2 \pm 1.8$	T $58.8 \pm 3.5$ trabecular bone area fraction C $47.2 \pm 7.7$ trabecular bone area fraction	–
Barone et al. (2013a)*†	GBR vs. unassisted healing	T $-1.1 \pm 0.96$ C $-2.1 \pm 0.6$	T $-0.3 \pm 0.76$ C $-1 \pm 0.7$	T $-1.6 \pm 0.55$ C $-3.6 \pm 0.72$	–	<i>Changes in width of keratinised gingiva</i> T $+1.14 \pm 0.8$ C $+0.73 \pm 0.8$
Barone et al. (2013b)‡	GBR (T1) vs. GBR (T2)	–	–	–	T1 $28.5 \pm 20$ VB T2 $31.4 \pm 18.1$ VB	–
Barone et al. (2014)†	GBR (T1) vs. GBR (T2)	T1 $-1.1 \pm 0.9$ T2 $-0.6 \pm 0.7$	T1 $-0.3 \pm 0.7$ T2 $-0.4 \pm 0.5$	T1 $-1.7 \pm 0.6$ T2 $-3.5 \pm 0.9$	–	<i>Changes in width of keratinised gingiva</i> T1 $+1.8 \pm 0.8$ T2 $-1.7 \pm 0.6$
Beck and Mealey (2010)	Grafting (T1) vs. grafting (T2)	<i>Data per socket</i> T1 $0.32 \pm 2.61$ T2 $-0.37 \pm 1.46$	–	<i>Data per socket</i> T1 $-1.43 \pm 1.89$ T2 $-1.47 \pm 1.89$	T1 $45 \pm 19.8\%$ new VB; $41.3 \pm 14.6\%$ CT; $13.5 \pm 12.2\%$ RGM T2 $45.8 \pm 22.4\%$ new VB; $39.6 \pm 13.0\%$ CT; $14.6 \pm 12.9\%$ RGM	–
Borg and Mealey (2015)†	GBR (T1) vs. GBR (T2)	T1 $-0.25 \pm 1.85$ T2 $0.26 \pm 2.08$	–	T1 $-1.63 \pm 1.18$ T2 $-1.19 \pm 1.36$	T1 $24.69 \pm 15.92$ VB; $27.04 \pm 13.62$ RGM; $48.27 \pm 14.16$ CT/other T2 $36.16 \pm 11.91$ VB; $18.24 \pm 12.47$ RGM; $45.38 \pm 11.09$ CT/other	–
Calasans-Maia et al. (2014)†	Grafting (T1) vs. grafting (T2)	–	–	T1 $-0.29 \pm 0.14$ T2 $-0.39 \pm 0.14$	T1 $33.6 \pm 7.1$ new VB area fraction; $32.3 \pm 8.8$ CT; $10.6 \pm 16.2$ RGM T2 $19.3 \pm 22.5$ new VB area fraction; $49.9 \pm 14$ CT; $22.5 \pm 7.9$ RGM	–
Camargo et al. (2000)*	Grafting vs. unassisted healing	T $-0.38 \pm 3.18$ C $-1 \pm 2.25$	–	T $-3.48 \pm 2.68$ C $-3.06 \pm 2.41$	–	–
Cardaropoli et al. (2014)	GBR vs. unassisted healing	<i>Data per socket</i> T $-0.56 \pm 0.45$ C $-1.67 \pm 0.43$	–	<i>Data per socket</i> T $-0.71 \pm 0.91$ C $-4.04 \pm 0.69$	–	–
Cook and Mealey (2013)	GBR (T1) vs. GBR (T2)	<i>Data per socket</i> T1 $-0.14 \pm 2.21$ T2 $0.03 \pm 2.81$	–	<i>Data per socket</i> T1 $-1.57 \pm 1.21$ T2 $-1.16 \pm 1.44$	T1 $32.8 \pm 14.7$ bone; $13.4 \pm 11.6$ RGM; $53.7 \pm 6.8$ CT/other T2 $47 \pm 9.1$ bone; RGM not detected; $53 \pm 9.1$ CT/other	–
Coomes et al. (2014)†	Grafting (T1) vs. grafting (T2)	T1 $4.75 \pm 2.65$ T2 $1.85 \pm 3.58$	–	T1 $-2.07 \pm 1.17$ T2 $-3.4 \pm 1.73$	–	–
Crespi et al. (2009a)‡	Grafting (T1) vs. grafting (T2) vs. unassisted healing	–	–	–	T1 $40 \pm 2.7$ VB; $41.3 \pm 1.3$ CT; $20.2 \pm 3.2$ RGM T2 $45 \pm 6.5$ VB; $41.5 \pm 6.7$ CT; $13.9 \pm 3.4$ RGM C $32.8 \pm 5.8$ VB; $64.6 \pm 6.8$ CT	–
Crespi et al. (2011a)‡	Grafting (T1) vs. grafting (T2) vs. grafting (T3)	–	–	–	T1 $36.5 \pm 2.6$ VB; $33.3 \pm 1.5$ CT; $32.2 \pm 3.2$ RGM T2 $38.0 \pm 16.2$ VB; $25.3 \pm 9.4$ CT; $36.6 \pm 4.8$ RGM T3 $30.3 \pm 4.8$ VB; $58.3 \pm 7.1$ CT	–
Crespi et al. (2011b)‡	Grafting vs. unassisted healing	–	–	–	T $39.6 \pm 9.4$ VB; $26.0 \pm 9.9$ CT; $34.4 \pm 5.1$ RGM C $29.5 \pm 5$ VB; $57.7 \pm 6.9$ CT	–
Eskow & Mealey (2014)‡	Grafting (T1) vs. grafting (T2)	–	–	–	Mean (range) T1 $16.1$ ( $12.1$ – $30.3$ ) new bone; $28.4$ ( $18.5$ – $37.5$ ) RGM; $52.9$ ( $47.4$ – $57.1$ ) CT/other T2 $13$ ( $10.1$ – $31$ ) new bone; $19.9$ ( $15.8$ – $24.3$ ) RGM; $62.8$ ( $50.9$ – $68.5$ ) CT/other	–

Table 3. (continued)

References	Comparison	Changes in vertical alveolar ridge dimensions – mid-buccal	Changes in vertical alveolar ridge dimensions – proximal	Changes in horizontal alveolar ridge dimensions	Histology (%)	Changes in keratinised tissues dimensions
Fernandes et al. (2011)	GBR (T1) vs. GBR (T2)	T1 $-1.2 \pm 2$ T2 $-1.5 \pm 1.2$	–	T1 $-2.5 \pm 1.8$ T2 $-3.4 \pm 1.4$	–	–
Festa et al. (2013)*	Grafting vs. unassisted healing	T $-0.6 \pm 1.4$ C $-3.1 \pm 1.3$	T $-0.3 \pm 0.8$ C $-0.4 \pm 1.2$	T $-1.8 \pm 1.3$ C $-3.7 \pm 1.2$	–	No changes to keratinised margin
Fiorellini et al. (2005)*,†	Grafting (T1) vs. grafting (T2) vs. grafting (T3) vs. unassisted healing	T1 $-0.6 \pm 1.4$ T2 $-0 \pm 1.2$ T3 $-1 \pm 1.4$ C $-1.2 \pm 1.2$	–	–	<i>Only descriptive</i> Bone structure of approximately two-thirds of samples was exclusively trabecular. Remodelling of woven bone into lamellar bone was the most common observation	–
Gholami et al. (2012)	GBR (T1) vs. GBR (T2)	–	–	<i>Data per socket</i> T1 $-1.1 \pm 1$ T2 $-0.9 \pm 0.6$	T1 $27.4 \pm 12.4$ total bone; $20.6 \pm 9.9$ RGM T2 $28.6 \pm 12.5$ total bone; $13.7 \pm 8.1$ RGM	–
Hoang & Mealey (2012)†	Grafting (T1) vs. grafting (T2)	T1 $-0.1 \pm 1.8$ T2 $0 \pm 1.9$	–	T1 $-1.4 \pm 1.5$ T2 $-1.3 \pm 1.5$	T1 $48.8$ VB; $8.2$ RGM; $43.1$ CT T2 $52.7$ VB; $5.4$ RGM; $41.9$ CT	–
Huh et al. (2011)†	Grafting (T1) vs. grafting (T2)	T1 $-0.1 \pm 1$ T2 $-1.1 \pm 1.4$	–	–	–	–
Isabella et al. (2003)*,†	GBR vs. unassisted healing	T $1.3 \pm 2$ C $-0.9 \pm 1.6$	T $-0.1 \pm 0.7$ C $-1 \pm 0.8$	T $-1.2 \pm 0.9$ C $-2.6 \pm 2.3$	T $28 \pm 14$ VB; $37 \pm 18$ non-vital; $26 \pm 11$ trabecular; $9 \pm 6$ amorphous C $54 \pm 12$ VB; – non-vital; $34 \pm 12$ trabecular; $12 \pm 9$ amorphous	<i>Changes in buccal gingival thickness</i> T $-0.1 \pm 0.5$ C $+0.4 \pm 0.6$
Jung et al. (2013)*	Grafting (T1) vs. sealing (T2) vs. sealing (T3) vs. unassisted healing	T1 $-2 \pm 2.4$ T2 $0 \pm 1.2$ T3 $1.2 \pm 2.9$ C $-0.5 \pm 0.9$	–	T1 $-6.1 \pm 2.5$ T2 $-1.2 \pm 0.8$ T3 $-1.4 \pm 1$ C $-3.3 \pm 2$	–	–
Karaca et al. (2015)	Sealing vs. unassisted healing	T $-0.012 \pm 1.24$ C $-1.42 \pm 1.5$	–	–	–	–
Kim et al. (2014)†	GBR (T1) vs. GBR (T2)	T1 $-1.2 \pm 0.8$ T2 $-1.5 \pm 1.1$	–	T1 $-1.1 \pm 1.3$ T2 $-1.2 \pm 1.3$	–	–
Lindhe et al. (2014)‡	Sealing (T1) vs. sealing (T2)	–	–	–	T1 $39.9 \pm 8.6$ mineralised bone; $1.8 \pm 2.5$ bone marrow; $1.6 \pm 1.8$ osteoid; $32.4 \pm 9.2$ fibrous tissue T2 $57.4 \pm 12.4$ mineralised bone; $7.1 \pm 6.1$ bone marrow; $7.3 \pm 4.9$ osteoid; $23.1 \pm 16.3$ fibrous tissue; $3.3 \pm 1.7$ vascular tissue $40 \pm 19$ bone (13.7–74.8); $25.7 \pm 13$ (0.6–51) RGM; $34.3 \pm 15$ (13.8–71.9) CT	–
Mardinger et al. (2012)‡	Sealing	–	–	–	–	–
Meloni et al. (2015)	Sealing (T1) vs. Sealing (T2)	T1 $-1.6 \pm 0.7$ T2 $-1.5 \pm 0.6$	–	T1 $-0.5 \pm 0.3$ T2 $-0.7 \pm 0.3$	–	–
Neiva et al. (2008)†	Grafting (T1) vs. grafting (T2)	T1 $0.2 \pm 1.8$ T2 $-0.6 \pm 1$	–	T1 $-1.3 \pm 1$ T2 $-1.4 \pm 1.1$	T1 $29.9 \pm 8.5$ VB; $65.3 \pm 6.4$ bone marrow and fibrous tissue; $6.3$ RGM T2 $36.5 \pm 7.7$ VB; $62.7 \pm 7.4$ bone marrow and fibrous tissue	–
Patel (2013)†	GBR (T1) vs. GBR (T2)	–	T1 $-0.4 \pm 1$ T2 $0.2 \pm 0.7$	T1 $-1.1 \pm 1$ T2 $-2.1 \pm 1$	<i>Only descriptive</i> Similar characteristics both groups. Newly formed bone mainly at apical part of biopsy. In coronal part, particles surrounded by	–

Table 3. (continued)

References	Comparison	Changes in vertical alveolar ridge dimensions – mid-buccal	Changes in vertical alveolar ridge dimensions – proximal	Changes in horizontal alveolar ridge dimensions	Histology (%)	Changes in keratinised tissues dimensions
Perelman-Karmon et al. (2012)‡	GBR (T1) vs. grafting (T2)	–	–	–	dense connective tissue with no signs of inflammation. No active resorption of graft particles T1 40.8 ± 10.6 total bone fraction T2 29.7 ± 7.2 total bone fraction	–
Pinho et al. (2006)	GBR (T1) vs. GBR (T2)	–	–	T1 –1.4 ± 1 T2 –1.4 ± 2	–	–
Poulias et al. (2013)†	GBR (T1) vs. GBR (T2)	T1 0.5 ± 2.9 T2 0.3 ± 2.6	T1 –0.5 ± 0.4 T2 –0.6 ± 0.4	T1 –1.6 ± 0.8 T2 –0.3 ± 0.9	T1 35 ± 16 VB; 21 ± 13 non-vital bone; 44 ± 9 trabecular space T2 40 ± 16 VB; 17 ± 11 non-vital bone; 43 ± 12 trabecular space	–
Serino et al. (2003)‡	Grafting vs. unassisted healing	–	–	–	<i>Only means provided</i> T 66.7 mineralised bone; RGM could not be identified C 43.67 mineralised bone	–
Vance et al. (2004)†	Grafting (T1) vs. GBR (T2)	T1 –0.3 ± 0.7 T2 0.7 ± 1.2	T1 –0.2 ± 0.7 T2 –0.5 ± 0.5	T1 –0.5 ± 0.8 T2 –0.5 ± 0.8	T1 61 ± 9 VB; 3 ± 3 RGM; 32 ± 10 trabecular; 4 ± 4 amorphous T2 26 ± 20 VB; 16 ± 7 RGM; 54 ± 15 trabecular; 5 ± 6 amorphous	<i>Changes in soft tissue thickness</i> T1 Buccal +0.1 ± 0.6; Lingual –0.1 ± 0.7 T2 Buccal –0.2 ± 1.5; Lingual 0 ± 0.7
Wallace et al. (2013)‡	GBR (T1) vs. GBR (T2)	–	–	–	Mean (range) T1 41.8 (16–66) VB; 6.6 (0–29) RGM; 51.6 (32–64) marrow/CT T2 32.5 (7 to 66) VB; 16.9 (0–29) RGM; 50.6 (34–65) marrow/CT	–
Wood and Mealey (2012)†	Grafting (T1) vs. grafting (T2)	T1 –0.4 ± 1.1 T2 –0.6 ± 1.2	–	T1 –2.2 ± 1.6 T2 –2.1 ± 1.7	T1 38.4 ± 14.5 VB; 8.9 ± 12.8 RGM; 52.7 ± 8 CT T2 24.6 ± 13.7 VB; 25.4 ± 17 RGM; 49.9 ± 11.1 CT	–

VB, vital bone; CT, connective tissue; RGM, residual graft material.  
 Data provided as mean ± SD unless noted otherwise; patient is unit of analysis unless specified otherwise; dimensional changes provided in millimetres.  
 All studies included for Question 2; highlighted studies included for Question 1.  
 \*Selected for meta-analysis Question 1.  
 †Selected for meta-analysis Question 2.  
 ‡Included only for histological data.

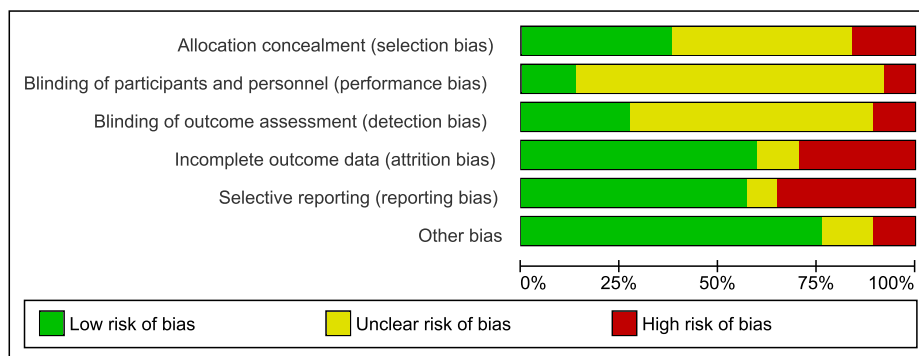


Fig. 2. Meta-analysis results and heterogeneity test for Q1; parallel studies. (a) Parallel studies investigating linear and volumetric changes in vertical alveolar bone height (mid-buccal), (b) split-mouth studies reporting on changes in the mid-buccal vertical alveolar ridge dimensions, (c) parallel studies investigating linear and volumetric changes in vertical alveolar bone height (proximal) and (d) parallel studies investigating linear and volumetric changes in alveolar bone width.

mean difference (SMD) in vertical mid-buccal bone height (mm) between ARP- and non-treated extraction sites was 0.739 mm (95% CI:

0.332 to 1.147). The difference between the ARP and control groups was found to be statistically significant ( $P < 0.001$ ).

*Split-mouth studies:* Three studies (Fig. 2) reported data on changes in the mid-buccal vertical alveolar ridge dimensions (Camargo et al. 2000; Festa et al. 2013; Karaca et al. 2015). There was a high level of heterogeneity ( $I^2 = 76.18\%$ ,  $P = 0.015$ ). The standardised mean difference (SMD) in vertical mid-buccal bone height (mm) between ARP- and non-treated extraction sites was 0.975 mm (95% CI: 0.017 to 1.933). The difference between the ARP and control groups was found to be statistically significant ( $P = 0.046$ ).

*Linear and volumetric changes in vertical alveolar bone height (proximal)*

*Parallel studies:* Three studies (Fig. 2) reported data on changes in the proximal vertical alveolar ridge dimensions (Iasella et al. 2003; Aimetti et al. 2009; Barone et al. 2013a). There was a low level of heterogeneity

( $I^2 = 24.53\%$ ,  $P = 0.2658$ ). The SMD proximal vertical bone height between ARP- and non-treated extraction sites was 0.796 mm (95% CI: 0.364 to 1.228). The difference between the ARP and control groups was found to be statistically significant ( $P < 0.001$ ).

*Split-mouth studies:* Only one study (Festa et al. 2013) reported on proximal bone changes in a split-mouth study. The mean change in proximal vertical bone height was  $-0.3 \pm 0.8$  mm in the test group and  $-0.4 \text{ mm} \pm 1.2$  in the control group. The difference between the measurements was not found to be statistically significant.

#### *Linear and volumetric changes in alveolar bone width*

*Parallel studies:* Four studies (Fig. 2) reported data on changes in the horizontal alveolar ridge dimensions (Iasella et al. 2003; Aimetti et al. 2009; Barone et al. 2013a; Jung et al. 2013). There was a high level of heterogeneity ( $I^2 = 91.37\%$ ,  $P < 0.0001$ ). The SMD in the horizontal bone width (mm) between ARP and non-treated extraction sites was 1.198 mm (95% CI:  $-0.0374$  to 2.433). The difference between the ARP and control groups was not found to be statistically significant ( $P = 0.057$ ).

*Split-mouth studies:* Two studies reported on changes in the horizontal bone measurements. There was a high level of heterogeneity ( $I^2 = 89.50\%$ ,  $P = 0.002$ ). An SMD of  $-0.161$  (95% CI:  $-0.866$  to 0.544) was calculated for Camargo et al. (2000), and 1.478 (95% CI: 0.652 to 2.304) for Festa et al. (2013).

#### *Histological characteristics of new bone formation*

Three studies (Iasella et al. 2003; Fiorellini et al. 2005 and Aimetti et al. 2009) reported on the histological composition of trephined bone core samples after ARP procedures. Aimetti et al. (2009) and Fiorellini et al. (2005) examined the differences in the trabecular bone levels following socket grafting procedures using alloplastic and xenograft/bioactive materials. Aimetti et al. (2009) found 100% of living bone in the bone sample following calcium sulphate socket grafting, with 58.8 (SD  $\pm 3.3$ )% trabecular bone in the test group and 47.2 (SD  $\pm 7.7$ )% in the control group. The difference in the bone content was found to be statistically significant ( $P < 0.001$ ). Greater levels of lamellar bone were found in the test group at coronal and apical sites, with higher levels of woven bone found at the same level in the control group. No inflammation was recorded in either the test or control group samples.

Although Fiorellini et al. (2005) did not report on the exact percentage of new bone formation for the different xenograft materials used, two-thirds of all the collected samples in each test group was found to be trabecular bone. No evidence of residual collagen matrix was found in the test group, with no difference recorded between the native and induced bone observed. Iasella et al. (2003) found more bone formation in the test group treated with FDBA and a collagen membrane (65  $\pm 10\%$ ) when compared to the unassisted socket healing controls (54  $\pm 12\%$ ). In the test group, 28% vital and 37% non-vital FDBA fragments were observed. The residual FDBA particles were often surrounded by woven bone or occasionally encapsulated in fibrous connective tissue. The core samples examined by Fiorellini et al. (2005), Iasella et al. (2003) did not demonstrate the presence of an inflammatory cellular response within the augmented bone.

#### *Changes in keratinised tissue width and thickness*

Three studies reported on the change in the keratinised tissue characteristics following ARP, two studies (Barone et al. 2013a; Festa et al. 2013) following a GBR procedure and one (Iasella et al. 2003) following socket grafting (Table 3). Barone et al. (2013a) reported an increase in the width of the keratinised tissue in both the test and the control groups (1.14  $\pm 0.8$  mm and 0.73  $\pm 0.8$  mm), with the test group having a greater shift of the gingival tissue towards the occlusal direction after ARP. Iasella et al. (2003) found that a loss in the gingival tissue thickness of  $-0.1$  (SD  $\pm 0.5$ ) mm occurred following GBR using a collagen membrane and allograft material, with a tissue gain of 0.4 (SD  $\pm 0.6$ ) mm in the unassisted control group. The difference between the test and the control groups was found to be statistically significant ( $P < 0.05$ ). Festa et al. (2013) reported on the gingival tissue height following socket grafting using a combination of porcine xenograft and cortical membrane. This study indicated no change to the free gingival margin at the neighbouring teeth following tooth extraction in the test and the control groups.

#### *Post-operative complications and patient-based outcomes*

All nine of the included studies reported on the occurrence of adverse events (Table 4). Five studies (Camargo et al. 2000; Aimetti et al. 2009; Barone et al. 2013a; Festa et al. 2013; Jung et al. 2013) reported no adverse

events during the healing phase in the ARP test and control groups. One study did not provide any information on complications (Iasella et al. 2003). Three studies (Fiorellini et al. 2005; Cardaropoli et al. 2014; Karaca et al. 2015) reported a high level of complications in both interventional and control groups. The complications reported in both groups were mainly oedema, oral pain and erythema (Fiorellini et al. (2005); Karaca et al. (2015) found that the frequency of these complications was greater in the ARP group. No studies reported on other variables associated with the patient experience in the test or the control group.

### **Outcome of controlled studies answering focused question 2**

#### GBR

#### *Linear and volumetric changes in vertical alveolar bone height (mid-buccal)*

Meta-analysis of seven studies and eleven subgroups calculated a pooled effect size of  $-0.467$  mm (95% CI:  $-0.866$  to  $-0.069$ ) reduction in the mid-buccal alveolar ridge height. The degree of variance in the studies was high. Allograft ARP appeared to be associated with a greater range of dimensional change (Iasella et al. 2003; Poulias et al. 2013; Borg & Mealey 2015).

#### *Proximal vertical bone change*

Meta-analysis of six studies and nine subgroups calculated an effect size of  $-0.356$  mm (95% CI:  $-0.490$  to  $-0.222$ ) reduction in the proximal vertical bone height. The degree of variance in the studies was moderate.

#### *Horizontal changes*

Eight studies with 13 subgroups calculated a pooled effect size of  $-1.45$  mm (95% CI:  $-1.892$  to  $-1.008$ ) reduction in the horizontal bone width. The degree of variance in the studies was high.

### **Socket grafting**

#### *Vertical mid-buccal bone changes*

Nine studies with sixteen subgroups calculated a pooled effect size of  $-0.157$  mm (95% CI:  $-0.554$  to 0.239) reduction in the vertical bone height. The degree of variance in the studies was high. Two studies (Neiva et al. 2008; Coomes et al. 2014) reported positive vertical height changes when the socket graft was covered with a xenograft collagen sponge.

**Table 4. Study outcomes of included papers (II) and Search strategy**

References	Complications
(a) Study outcomes of included papers (II)	
Aimetti et al. (2009)	None reported
Barone et al. (2013a)	None reported
Barone et al. (2013b)	–
Barone et al. (2014)	None reported
Beck and Mealey (2010)	T1: post-operative infection (2 sites, 2 patients); deficient fill of socket at 7- to 10-day follow-up (3 patients) T2: post-operative infection (1 patient)
Borg and Mealey (2015)	None reported
Calasans-Maia et al. (2014)	None reported
Camargo et al. (2000)	None reported
Cardaropoli et al. (2014)	Discomfort and swelling were commonly reported in both groups
Cook and Mealey (2013)	T1: apparent post-operative infections at the treatment site that resolved within 1 week after switching antibiotic regimens (1 patient) T2: apparent post-operative infections at the treatment site that resolved within 1 week after switching antibiotic regimens (1 patient), patient reported removing the OP membrane during the initial 2 weeks of healing (1 patient)
Coomes et al. (2014)	Mild erythema and localised post-operative swelling 2–3 days after extraction (12% of patients)
Crespi et al. (2009a)	–
Crespi et al. (2011a)	None reported
Crespi et al. (2011b)	None reported
Eskow & Mealey (2014)	T1: 1 site lost graft particles from the socket during initial healing which was seen at 1 week post-operative
Fernandes et al. (2011)	None reported
Festa et al. (2013)	None reported
Fiorellini et al. (2005)	A total of 250 adverse events were reported for 78 of 80 patients. The most frequent reports were oral oedema (75%), mouth pain (68%) and oral erythema (46%). There were a greater number of cases of oral oedema and erythema in treatment groups compared to the no treatment group
Gholami et al. (2012)	None reported
Hoang & Mealey (2012)	T2: sequestering of some superficial pieces of bone graft material at the 1-week recall (2 patients)
Huh et al. (2011)	–
Iasella et al. (2003)	–
Jung et al. (2013)	None reported
Karaca et al. (2015)	All patients experienced mild to moderate pain at donor site
Kim et al. (2014)	No severe adverse events reported
Lindhe et al. (2014)	–
Mardinger et al. (2012)	–
Meloni et al. (2015)	None reported
Neiva et al. (2008)	–
Mardas (2010)	Few patients in both groups reported minor post-operative pain or discomfort, localised oedema and in some cases exfoliated graft particles were observed. All the patients presented with membrane exposure at the first post-operative week that, in most cases, became larger during the second week
Perelman-Karmon et al. (2012)	None reported
Pinho et al. (2006)	Exposure of membrane in 5 of the 10 treated subjects between the sixth and tenth week of the placements
Poulias et al. (2013)	None reported
Serino et al. (2003)	None reported
Vance et al. (2004)	–
Wallace et al. (2013)	None reported
Wood and Mealey (2012)	T1: 2 patients showed signs of potential infection at 1 week T2: 1 patient showed signs of potential infection at 1 week
All studies included for Question 2; highlighted studies included for Question 1.	

**Proximal vertical bone changes**

Only two groups from two studies (Vance et al. 2004; Aimetti et al. 2009) reported on proximal vertical bone changes following socket seal procedures. Meta-analysis was therefore not attempted. A proximal vertical bone height change of  $-0.2$  mm was

calculated for Aimetti et al. (2009) (95% CI:  $-0.451$  to  $0.051$ ) and  $-0.2$  mm for Vance et al. (2004) (95% CI:  $-0.596$  to  $0.196$ ).

**Horizontal bone changes**

Eight studies with thirteen subgroups calculated a pooled effect size reduction in the

horizontal bone dimension of  $-1.613$  mm (95% CI:  $-1.989$  to  $-1.238$ ). The degree of variance in the studies was moderate.

**Socket sealing ARP**

Only two eligible studies (Jung et al. 2013; Meloni et al. 2015) reported on dimensional bone changes following ARP with socket sealing. Their results were found to be divergent. Jung et al. (2013) reported a vertical change of  $0 \pm 1.2$  mm and a width reduction of  $-1.2 \pm 0.8$  mm following socket seal with a porcine collagen matrix (Mucograft) and a vertical height gain of  $1.2 \pm 2.9$  mm and a horizontal reduction of  $-1.4 \pm 1$  mm following socket seal with a free gingival graft. Meloni et al. (2015) reported a height reduction of  $-1.6 \pm 0.69$  mm and width reduction of  $-0.54 \pm 0.25$  mm with a porcine collagen matrix, and height reduction of  $-1.47 \pm 0.58$  mm and  $-0.67 \pm 0.31$  mm width reduction when using a connective tissue graft. Both studies did not report a statistical difference between the two socket seal interventional groups.

**Changes in keratinised tissue width and thickness**

Seven groups from five studies (Iasella et al. 2003; Vance et al. 2004; Barone et al. 2013a, 2014; Festa et al. 2013) reported on keratinised tissue dimensions or gingival tissue thickness following ARP procedures (Table 3). Five groups from four studies (Iasella et al. 2003; Vance et al. 2004; Barone et al. 2013a, 2014) had undergone GBR, with two groups from two studies (Vance et al. 2004; Festa et al. 2013) socket grafting procedures.

Two studies (Barone et al. 2013a, 2014) reported on an increase in the width of keratinised tissue of, respectively,  $1.14 \pm 0.8$  mm and  $1.18 \pm 0.8$  mm when GBR procedures were carried out. Barone et al. (2014) indicated a reduction in keratinised tissue width  $-1.7 \pm 0.6$  mm when a GBR technique was combined with a coronally advanced flap for primary closure. Festa et al. (2013) did not report a change to the keratinised tissue margin when a socket grafting procedure was undertaken.

The thickness of the keratinised tissue margin was reported to be reduced by  $-0.1 \pm 0.5$  mm (Iasella et al. 2003) and  $-0.2 \pm 1.5$  mm (Vance et al. 2004) when GBR procedures were undertaken. An increase in thickness was reported in a combination grafting procedure (Vance et al. 2004)  $0.1 \pm 0.6$  mm.

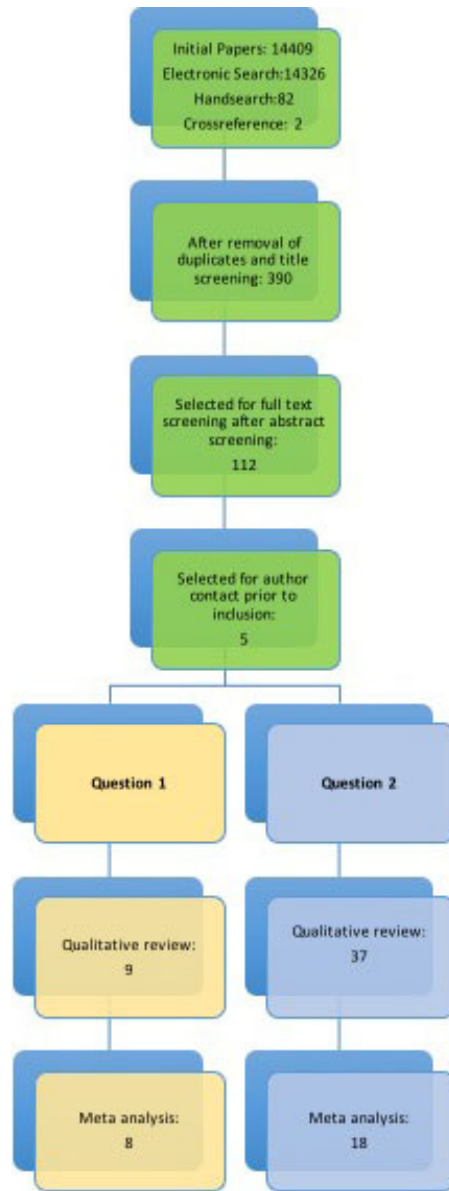
Vance et al. (2004) reported on a reduction  $-0.1 \pm 0.7$  mm in the lingual keratinised tissue when a socket grafting procedure was



Table 4. (continued)

(b) Search strategy

	Allocation concealment (selection bias)	Blinding of participants and personnel (performance bias)	Blinding of outcome assessment (detection bias)	Incomplete outcome data (attrition bias)	Selective reporting (reporting bias)	Other bias
Aimetti 2009	?	?	?	+	?	?
Barone 2013a	?	?	?	+	+	+
Barone 2013b	+	?	?	+	+	+
Barone 2014	+	+	+	+	?	+
Beck 2010	+	+	+	+	+	+
Borg 2015	+	?	?	+	+	+
Calasans-Maia 2014	+	?	?	+	+	+
Camargo 2000	?	?	?	+	+	+
Cardaropoli 2014	?	?	+	+	?	+
Cook 2013	?	?	?	+	+	+
Coomes 2014	+	+	?	+	+	+
Crespi 2009	+	?	?	+	+	+
Crespi 2011a	+	?	?	+	+	+
Crespi 2011b	?	?	?	+	+	+
Eskow 2013	?	?	?	+	+	+
Fernandes 2011	?	?	?	+	+	+
Festa 2013	?	?	?	+	+	+
Fiorellini 2005	+	+	+	?	+	?
Gholami 2012	+	?	+	+	+	+
Hoang 2012	?	?	?	+	+	+
Huh 2011	?	?	?	?	+	+
Iasella 2003	?	?	+	+	+	+
Jung 2013	+	?	?	?	+	+
Karaca 2015	+	+	+	+	+	?
Kim 2014	?	?	?	+	+	+
Lindhe 2014	?	?	?	?	+	+
Mardas 2010	+	+	+	+	+	+
Mardinger 2012	+	+	+	+	+	+
Meloni 2015	+	?	+	+	+	+
Neiva 2008	+	+	+	+	+	+
Perelman-Karmon 2012	+	?	+	+	+	+
Pinho 2006	+	?	?	+	+	?
Poulias 2013	+	?	?	+	+	+
Serino 2003	?	?	?	+	+	+
Vance 2004	?	?	?	+	+	+
Wallace 2013	+	?	?	+	+	?
Wood 2012	?	?	+	+	+	+



performed but no changes were observed (0.0 ± 0.7 mm) when using a GBR procedure.

**Histological characteristics of new bone formation**

The histological characteristics of the new tissue, formed within the socket following ARP, were described in 24 studies (Iasella et al. 2003; Serino et al. 2003; Vance et al. 2004; Fiorellini et al. 2005; Neiva et al. 2008; Aimetti et al. 2009; Crespi et al. 2009, 2011a, b; Beck & Mealey 2010; Mardas et al. 2010; Gholami et al. 2012; Hoang & Mealey 2012; Mardinger et al. 2012; Perelman-Karmon et al. 2012; Wood & Mealey 2012; Barone et al. 2013b; Cook & Mealey 2013; Poulias et al. 2013; Wallace et al. 2013; Calasans-Maia et al. 2014; Eskow & Mealey 2014; Lindhe et al. 2014; Borg & Mealey 2015).

Only a descriptive analysis was undertaken in this section, as extensive variation was present in the treatment protocols and biomaterials materials used as well as in the histological methods applied to evaluate socket healing. Bone histological samples were reported upon by descriptive analysis, percentage tissue composition (bone/connective tissue/residual particles), mineralised bone content (Aimetti et al. 2009; Gholami et al. 2012; Barone et al. 2013b) and cellular bone composition (cellular/acellular/trabecula). The included studies reported on the histological characteristics of the trephined core samples over a 10-week to 9-month period. The majority of the reports examined histological composition of the core samples at 3 months of healing.

**GBR procedures**

Seventeen groups from ten studies (Barone et al. 2013b – two groups, Borg & Mealey 2015 – two groups, Cook & Mealey 2013 – two groups, Gholami et al. 2012 – two groups, Iasella et al. 2003; Mardas et al. 2010 – two groups, Perelman-Karmon et al. 2012; Poulias et al. 2013 – two groups, Vance et al. 2004; Wallace et al. 2013 – two groups) report on histological composition of bone samples following GBR procedures. The results from these studies showed a high level of variation in the total bone percentage recorded with a range between 47.9 ± 9.1% to 24.67 ± 15.92% reported. Four studies (Barone et al. 2013b; Borg & Mealey 2015 – one group, Gholami et al. 2012 – two groups and Vance et al. 2004) reported a total bone composition of <30%, five (Barone et al. 2013b – one group, Borg & Mealey 2015 – one group, Cook & Mealey 2013 – one group, Poulias et al. 2013 – one group and Wallace et al. 2013 – one group) found a 30-40% bone percentage and four (Cook & Mealey 2013 – one group, Perelman-Karmon et al. 2012 – one group, Poulias et al. 2013 – one group and Wallace et al. 2013 – one group) reporting over 40%. The use of a combined FDBA and DFDBA (Borg & Mealey 2015) or collagen/alloplast (Cook & Mealey 2013) graft produced statistically more bone (P < 0.05) when compared with a control using a single allograft or xenograft. The addition of denatured allograft material (Borg & Mealey 2015) significantly lowered the percentage of residual graft particle (P = 0.035). The addition of a bone growth factor also increased the percentage of composition (Wallace et al. 2013). No qualitative differences were recorded between ceramic composite and DBBM (Mardas et al. 2010) or when different xenografts were tested (Barone et al. 2013b). The depth of

the core sample was found to statistically ( $P < 0.001$ ) influence the bone composition in one study (Perelman-Karmon et al. 2012). Residual and/or encapsulated graft particles were found in five studies (Vance et al. 2004; Mardas et al. 2010; Cook & Mealey 2013; Wallace et al. 2013; Borg & Mealey 2015), with the percentage of residual graft particles ranging from 3 to 16.9%.

#### Socket grafting procedures

Twenty-four groups from fourteen studies (Aimetti et al. 2009; Beck & Mealey 2010 – two groups, Calasans-Maia et al. 2014 – two groups, Crespi et al. 2009 – two groups, Crespi et al. 2011a – three groups, Crespi et al. 2011b; Eskow & Mealey 2014 – two groups, Fiorellini et al. 2005 – three groups, Hoang & Mealey 2012 – two groups, Neiva et al. 2008 – two groups, Perelman-Karmon et al. 2012 – one group, Serino et al. 2003; Vance et al. 2004 and Wood & Mealey 2012 – two groups) reported on histological composition following various socket grafting procedures. The average trabecular bone composition was recorded by Aimetti et al. (2009) to be 58.8% with Fiorellini et al. (2005) finding a bone level of 66.6%. Eskow & Mealey (2014) reported on new bone formation (range 13–16.13%), Perelman-Karmon et al. (2012) reported on a total bone fraction (range 29.7–40.8%), and Serino et al. (2003) measured the average mineralised bone percentage (66.7%). The composition of vital bone formation recorded was highly variable, with the percentage recorded ranging from 19.3% (Beck & Mealey 2010) to 61% (Vance et al. 2004). Three studies (Calasans-Maia et al. 2014 – one group, Neiva et al. 2008; Vance et al. 2004) reported a vital bone composition of less than 30%, four studies (Calasans-Maia et al. 2014 – one group, Crespi et al. 2011a – two groups, Crespi et al. 2011b; Wood & Mealey 2012) reported a vital bone composition of 30–40%, and four studies (Beck & Mealey 2010 – two groups, Crespi et al. 2009 – two groups, Hoang & Mealey 2012 – two groups and Vance et al. 2004) reported a vital bone composition of more than 40%. No statistical difference was recorded in the vital bone composition when different alloplasts, allografts and xenografts were compared (Beck & Mealey 2010; Crespi et al. 2011a; Hoang & Mealey 2012; Calasans-Maia et al. 2014). Eskow & Mealey (2014) did not observe a statistical difference between cortical or cancellous graft material, and Hoang & Mealey (2012) failed to observe a difference when using different sized particles of human demineralised bone matrix. A significant difference in the

trabecular bone formation was found when human growth hormone or calcium sulphate was added to the graft material (Vance et al. 2004; Fiorellini et al. 2005; Neiva et al. 2008; Crespi et al. 2009). Demineralised freeze-dried allograft generated more vital bone formation when socket grafting using methylcellulose, calcium sulphate and bone allograft was compared against GBR using a bovine xenograft and collagen membrane (Vance et al. 2004). More vital bone was also recorded when socket grafting was undertaken with a demineralised rather than mineralised freeze-dried bone allograft (Wood & Mealey 2012). Residual and/or encapsulated graft particles were found in twelve studies (Serino et al. 2003; Vance et al. 2004; Neiva et al. 2008; Crespi et al. 2009, 2011a,b; Beck & Mealey 2010; Hoang & Mealey 2012; Wood & Mealey 2012; Calasans-Maia et al. 2014 and Eskow & Mealey 2014), with the percentage of residual graft particles ranging from 0% with a polylactide sponge (Serino et al. 2003) to 36.6% with a corticocancellous xenogenic graft (Crespi et al. 2011a). No inflammatory response was reported within the histological graft specimens.

#### Socket seal

Three groups from two studies (Lindhe et al. 2014 – two groups and Mardinger et al. 2012) reported on bone composition following a socket seal procedure. Lindhe et al. (2014) examined the effect of socket sealing with a collagen membrane or membrane/bovine xenograft combination. Mardinger et al. (2012) evaluated the additional benefit of using the reactive socket tissue as a seal overlying a bovine xenograft. Histological examination by Lindhe et al. (2014) reported  $39.9 \pm 8.6\%$  mineralised bone and  $19.5 \pm 6.5\%$  residual graft in the group combining xenograft with a collagen seal, and  $57.4 \pm 12.4\%$  mineralised bone in the collagen seal alone group. Mardinger et al. (2012) reported  $40 \pm 19\%$  vital bone in the core samples. Three studies (Mardas et al. 2010; Cook & Mealey 2013; Lindhe et al. 2014) reported fibrous encapsulation of graft particles, with four studies (Crespi et al. 2011b; Hoang & Mealey 2012; Lindhe et al. 2014; Borg & Mealey 2015) reporting new bone formation in direct contact with the graft particles with inflammation recorded in the healed overlying gingival tissues.

#### Histological characteristics of new bone formation

The depth of the core sample was found to positively influence the composition of new

bone formation, with a larger percentage of new bone found in the apical section of the core (Aimetti et al. 2009; Perelman-Karmon et al. 2012). Three studies (Cook & Mealey 2013; Mardas et al. 2010; Lindhe et al. 2014) reported fibrous encapsulation of graft particles, with four studies (Crespi et al. 2011b; Hoang & Mealey 2012; Lindhe et al. 2014; Borg & Mealey 2015) reporting new bone formation in direct contact with the graft particles. No studies reported on signs of inflammation within the histological samples. Although inflammatory cells were a common finding in the core biopsies after ARP, loose graft particles and remnants of the membrane were not usually seen.

#### Post-operative complications

The presence and absence of complications were reported in twenty-nine studies (Camargo et al. 2000; Serino et al. 2003; Fiorellini et al. 2005; Pinho et al. 2006; Aimetti et al. 2009; Beck & Mealey 2010; Mardas et al. 2010; Crespi et al. 2011a,b; Fernandes et al. 2011; Gholami et al. 2012; Hoang & Mealey 2012; Perelman-Karmon et al. 2012; Wood & Mealey 2012; Barone et al. 2013a, 2014; Cook & Mealey 2013; Festa et al. 2013; Jung et al. 2013; Poulias et al. 2013; Wallace et al. 2013; Calasans-Maia et al. 2014; Cardaropoli et al. 2014; Coomes et al. 2014; Eskow & Mealey 2014; Kim et al. 2014; Borg & Mealey 2015; Karaca et al. 2015; Meloni et al. 2015).

The most common findings were soft tissue inflammation and possible infection (Fiorellini et al. 2005; Beck & Mealey 2010; Mardas et al. 2010; Wood & Mealey 2012; Cook & Mealey 2013; Wallace et al. 2013; Coomes et al. 2014; Karaca et al. 2015). Loose graft particles or deficient socket fill at the ARP site was reported in three socket grafting groups (Beck & Mealey 2010 – one group, Hoang & Mealey 2012; Eskow & Mealey 2014) and one GBR (Mardas et al. 2010) study. Patient discomfort was reported in four studies (Fiorellini et al. 2005; Mardas et al. 2010; Cardaropoli et al. 2014; Karaca et al. 2015). Membrane exposure was recorded in three GBR studies following surgical intervention (Pinho et al. 2006; Mardas et al. 2010; Cook & Mealey 2013).

#### Patient-based outcomes

No studies reported on patient preferences or any other patient-based outcomes following ARP preservations.

#### Quality assessment & risk of bias

The quality assessment of all the included studies for both focused questions is

presented in Table 4a and b. Only two studies were assessed as having low risk (Neiva et al. 2008; Mardas et al. 2010). Three other studies were assessed as having a low risk of bias in all but one domain (Gholami et al. 2012; Barone et al. 2014; Meloni et al. 2015), and three studies presented with a low risk of bias in four domains (Huh et al. 2011; Calasans-Maia et al. 2014; Borg & Mealey 2015). All other studies were considered to have an unclear to high risk of bias.

Other sources of bias were the lowest risk category reported when examining the papers, with uncertainty in the blinding of the participants and the outcome assessment, the commonest finding in the papers examined. The highest risk of bias was associated with selective reporting.

## Discussion

### Objectives and main findings

Augmentation procedures have been proposed as a method to limit the adverse functional and volumetric tissue changes experienced during healing after a tooth extraction (Tan et al. 2012; Vignoletti et al. 2012; Mardas et al. 2015). They have been recorded as changing the structural and histological characteristics of the bone and gingival tissue (Block & Kent 1990; Lindhe et al. 2014; Tan et al. 2012; Horvath et al. 2013; Vignoletti et al. 2014), possibly promoting the establishment of an idealised functional, biologic and aesthetic foundation, before implant-supported or conventional prostheses are provided (Mardas et al. 2015).

The adoption of ARP has been proposed as a method to significantly improve the aesthetic outcome of single-tooth implants, particularly in the anterior maxilla as it has been reported that they may help to retain sufficient bone at dental implant sites to allow fixture placement (Mardas et al. 2015), reduce the risk of subsequent bone loss (Horvath et al. 2013), positively influence the design of the prosthetic tooth (Pagni et al. 2012), improve the emergence profile of the restoration (Belser et al. 2004) and to simplify access for oral hygiene activities. Anticipated soft tissue effects have included an increase in the gingival papilla height and expansion of the fixed keratinised tissue height and width.

Although there is recognition that augmentation protocols can be used to preserve bone and soft tissues, heterogeneity of the published data has led Vignoletti et al. (2012), Horvath et al. (2013), Mardas et al. (2015) to

conclude that further research was required to develop a clearer understanding of the variability and characteristics of the clinical outcomes attributed to each grafting procedure, particularly as differences have been recorded in the quality and composition of the supporting bone (Lindhe et al. 2014).

This systematic review has been designed to evaluate the increased available evidence from RCTs, CCT and large prospective case series reporting on ARP procedures and to determine whether additional clarity has been established regarding the advantage and disadvantages of alternative treatment modalities.

This review found significantly less vertical alveolar bone height resorption when ARP was compared to unassisted socket healing. These findings are in agreement with the results published by Horvath et al. (2013), Vignoletti et al. (2011) and Morjaria et al. (2014). Although a mean reduction in alveolar bone width resorption of 1.20 mm was recorded, this observation was not found to be statistically significant when compared to unassisted socket healing. This conclusion is at odds with that reported by Vignoletti et al. (2011), but the difference may be accounted for by the heterogeneity of the included data, the methodological structure of the review and the limited number of included trials reporting on this finding. When this study was compared with the systematic review performed by Vignoletti et al. (2012), it was found that seven of the twelve studies identified by Vignoletti et al. (2012), did not perform statistical analysis and that three of the remaining five studies were excluded from this systematic review due to insufficient patient numbers, duplicate reporting and incompatible study design.

Histologically, an increase in bone content was found in the ARP group in comparison with the control group. This was also reported in the systematic review by De Risi et al. (2013) and in certain groups in the systematic review by Horvath et al. (2013). ARP studies, however, reported a higher level of complications and an increased frequency of oedema, facial pain and erythema (Fiorellini et al. 2005; Karaca et al. 2015).

No studies reported on other variables associated with the patient experience.

Although various surgical techniques and materials have been used for ARP, no material or type of ARP intervention can be claimed to yield superior results to another (De Risi et al. 2013; Horvath et al. 2013; Mardas et al. 2015). Previous systematic reviews concluded that the use of barriers for GBR appeared to be more effective in

limiting post-extraction dimensional changes of the alveolar ridge (Vignoletti et al. 2012; Horvath et al. 2013; Avila-Ortiz et al. 2014). Although direct statistical comparison was not possible, a greater vertical bone dimensional change was recorded following GBR when compared with the dimensional findings for socket grafting. The amount of horizontal bone dimensional change was noted to be greater with socket grafting than that reported for GBR procedures.

Keratinised tissue measurements were not commonly reported following ARP procedures. This is surprising as the conservancy of the fixed keratinised tissues might affect long-term peri-implant health and decrease the risk for biologic complications (Tan et al. 2012) if an implant-supported restoration is considered. GBR techniques appeared to result in an increase in the keratinised tissue width when no attempt at primary closure was undertaken. No change in the soft tissue width was reported when socket grafting was used. The thickness of the gingival tissues was slightly reduced with GBR procedures (Iasella et al. 2003; Vance et al. 2004), with a small gain noted when using a combination of collagen/particulate socket graft (Vance et al. 2004).

The use of GBR or socket grafting techniques in this systematic review seemed to produce a similar range of bone composition (vital and trabecular bone) in histological samples. The effect of using different GBR, socket grafting materials and particle size on new bone formation was inconclusive, as no statistical advantage was reported in the reviewed RCTs. Demineralised freeze-dried bone was reported as having a statistical influence on the creation of the new vital bone fraction in socket grafting techniques. More vital bone was reported in the apical area of core samples, when compared with coronal sections.

The depth of the core sample was found to influence the bone composition (Aimetti et al. 2009; Perelman-Karmon et al. 2012). Although the presence of residual graft particle has been recorded as interfering or disrupting the process of bone healing, only three of the twenty-four studies (Mardas et al. 2010; Cook & Mealey 2013; Lindhe et al. 2014) reported on fibrous encapsulation of the graft particles, with no studies reporting on inflammation within the core samples.

The incidence of complications reported within the ARP studies was low. Loose graft particle or deficient socket fill was the commonest adverse event in socket graft

procedures (Beck & Mealey 2010; Hoang & Mealey 2012; Eskow & Mealey 2014), with exposure of the membrane reported in three of ten included GBR studies. An exposure of the graft particle was associated with the presence of fibrous encapsulation within the histological specimen (Cook & Mealey 2013).

#### Strength and weakness of the systematic review

As in the previous systematic review by our group (Mardas et al. 2015), two focus questions were formulated to try to ensure that all available relevant information on ARP was included in the study. The first focused question limited inclusion to RCTs, CCTs and prospective cohort studies with a control group of unassisted socket healing, in order to identify comparative site dimensional and qualitative tissue effects following ARP procedures. This was based on the fact that the clinical merit of applying ARP is based on the assumption that they will have an additional positive effect on tissue conservancy and bone characteristics over unassisted healing and will validate use of the procedure. For the second focused question, controlled studies without a control group and large prospective case series were also included, to ensure that as much of the available published data was used to estimate pooled tissue changes according to three types of interventions for ARP.

Although a comprehensive search strategy including five databases, extensive hand-search and cross-reference search and no language restriction were applied, it is possible that some grey literature may not have been included as only published studies were selected. In order to obtain as much data as possible from published studies, the authors of five studies selected for full-text screening were contacted via email to request further information relating to the dimensional and histological changes following ARP. Some authors failed to respond within the requested period of time; therefore, it is possible that further information exists which could be used to complement the data set used in this review.

The total number of subjects and selected studies for focused questions 1 and 2 could be considered sufficient for the assessment of effect size differences between ARP and unassisted socket healing and to calculate mean bone and soft tissue dimensional changes following GBR and socket grafting ARP procedures. Limited data was available, however, to evaluate the influence of socket seal techniques on site dimensional changes,

histological characteristics and patient outcome factors and as a result the findings in this section of the analysis should be interpreted with caution. Finally, the sample sizes of all the selected clinical trials were relatively small, with many not including a sample size calculation. This may have reduced the power of the studies.

#### Confounding factors

##### Socket wall

As the majority of studies in this systematic review had at least three walls of the socket intact, with more than 50% of the fourth wall remaining intact, the impact of socket wall integrity on the ARP outcome is relatively unknown. The tooth extraction sites were recorded as being heterogeneous, minimising the effect of the position of the extracted teeth on the outcomes.

##### Measurements

The method used to measure the alveolar bone dimensions varied in several studies. Twenty-two of the 27 included studies used direct measurements from static casts, in preference to CBCT radiographic images. As static cast measurements can be influenced by the impression technique and soft tissue changes, difference in the effect of the intervention may have occurred. The possible variation that this may have caused in the recorded measurements was not considered in this review.

##### Patient-based outcomes

As a significant number of publications did not report on this finding, then there may be a higher risk of under-reporting.

##### Antimicrobial use

Antibiotics were commonly prescribed as an adjunct to ARP, with extensive variation in prescription pattern, dose and length of use. Antibiotic prophylaxis in alveolar and implant surgical procedure has been shown to have a small statistic effect on healing and outcome Esposito et al. (2008). The impact of this variable was not considered as a component of this review.

#### Conclusion

Within the limitations of this study, the following conclusions can be drawn:

- ARP results in a significant reduction in the vertical bone dimensional change following tooth extraction when compared to unassisted socket healing.

- A reduction in horizontal alveolar bone dimensional change was found when ARP was compared to unassisted socket healing, but the difference between techniques was not found to be statistically significant.
- No evidence was identified to clearly indicate the superior impact of a type of ARP intervention (GBR, socket filler and socket seal) on bone dimensional preservation or keratinised tissue dimensions. Currently, it is not known whether a bio-material or a treatment protocol is superior to others.
- There is insufficient evidence to demonstrate a difference in the amount of vital bone formation following GBR or socket grafting techniques.
- Inflammation was common following ARP.
- The majority of the studies evaluating ARP procedures presented with high or unclear risk of bias. Clinical recommendations derived from this study should be interpreted with caution.

#### Recommendations for further research

- There is still a need for high-quality RCTs on adequately powered sample sizes to evaluate differences in outcomes between different ARP procedures and unassisted socket healing. Socket seal procedures should be further investigated in comparison with other ARP interventions.
- The role of possible confounding factors such as smoking, reason for extraction, tooth type and location, integrity of buccal bone plate, flap reflection and closure and antibiotic usage should be further investigated.
- Patient-based outcomes and cost-benefit indicators should be included in future trials.

In all future trials, special emphasis should be given to the following issues:

1. Decrease in heterogeneity and control of reported sources of bias.
2. Radiographic assessment of marginal bone levels should be performed on standardised radiographs taken at specific period of times.
3. Soft tissue dimensional measurement should be standardised by using modern technologies like 3D computer-aided analysis.

## References

- Adriaens, P.A. & Van der Stede, N. (1998) Alveolar bone protection of extraction sites with a resorbable bilayer GBR membrane. *Journal of Dental Research* **77**: 777–790.
- Aimetti, M., Romano, F., Griga, F. & Godio, L. (2009) Clinical and histologic healing of human extraction sockets filled with calcium sulphate. *The International Journal of Oral & Maxillofacial Implants* **24**: 902–909.
- Amler, M.H. (1969) The time sequence of tissue regeneration in human extraction wounds. *Oral Surgery Oral Medicine Oral Pathology* **27**: 309–318.
- Araujo, M.G., Da Silva, J.C., De Mendonca, A.F. & Lindhe, J. (2015) Ridge alterations following grafting of fresh extraction sockets in man. A randomized clinical trial. *Clinical Oral Implants Research* **26**: 407–412.
- Artzi, Z., Tal, H. & Dayan, D. (2000) Porous bovine bone mineral in healing of human extraction sockets. part 1: histomorphometric evaluations at 9 months. *Journal of Periodontology* **71**: 1015–1023.
- Avila-Ortiz, G., Rodriguez, J.C., Rudek, I., Benavides, E., Rios, H. & Wang, H.L. (2014) Effectiveness of three different alveolar ridge preservation techniques: a pilot randomized controlled trial. *The International Journal of Periodontics and Restorative Dentistry* **34**: 509–521.
- Barone, A., Ricci, M., Tonelli, P., Santini, S. & Covani, U. (2013a) Tissue changes of extraction sockets in humans: a comparison of spontaneous healing vs. ridge preservation with secondary soft tissue healing. *Clinical Oral Implants Research* **24**: 1231–1237.
- Barone, A., Todisco, M., Ludovichetti, M., Gualini, F., Aggstaller, H. & Torres-Lagares, D. (2013b) A prospective, randomized, controlled, multi-centre evaluation of extraction socket preservation comparing two bovine xenografts: clinical and histologic outcomes. *The International Journal of Periodontics and Restorative Dentistry* **33**: 795–802.
- Barone, A., Toti, P., Piattelli, A., Iezzi, G., Derchi, G. & Covani, U. (2014) Extraction socket healing in humans after ridge preservation techniques: comparison between flapless and flapped procedures in a randomized clinical trial. *Journal of Periodontology* **85**: 14–23.
- Bartee, B.K. (2001) Extraction site reconstruction for alveolar ridge preservation. Part 2: membrane-assisted surgical technique. *Journal of Oral Implantology* **27**: 194–197.
- Beck, T.M. & Mealey, B.L. (2010) Histologic analysis of healing after tooth extraction with ridge preservation using mineralized human bone allograft. *Journal of Periodontology* **81**: 1765–1772.
- Becker, W., Urist, M., Becker, B., Jackson, W., Pony, D., Bartold, M., Vincenzzi, G., De Georges, D. & Niederwanger, M. (1996) Clinical and histological observations of sites implanted with intraoral autologous bone grafts or allografts. 15 human case reports. *Journal of Periodontology* **67**: 1025–1033.
- Belser, U., Buser, D. & Higginbottom, F. (2004) Consensus statements and recommended clinical procedures regarding aesthetics in implant dentistry. *International Journal of Oral & Maxillofacial Implants* **19**(Suppl): 73–74.
- Block, M.S. & Kent, J.N. (1990) Factors associated with soft and hard-tissue compromise of endosseous implants. *Journal of Oral Maxillofacial Surgery* **48**: 1153–1160.
- Borenstein, M., Hedges, L., Higgins, J. & Rothstein, H. (2009) Introduction to Meta-Analysis. London: Wiley.
- Borg, T.D. & Mealey, B.L. (2015) Histologic healing following tooth extraction with ridge preservation using mineralized versus combined mineralized-demineralized freeze-dried bone allograft: a randomized controlled clinical trial. *Journal of Periodontology* **86**: 348–355.
- Calasans-Maia, M., Resende, R., Fernandes, G., Calasans-Maia, J., Alves, A. & Granjeiro, J. (2014) A randomised controlled clinical trial to evaluate a new xenograft for alveolar socket preservation. *Clinical Oral Implant Research* **25**: 1125–1130.
- Camargo, P., Lekovic, V., Weinlaender, M., Klokkevold, P., Kenny, E., Dimitrijevic, B., Nedic, M., Jancovic, S. & Orsini, M. (2000) Influences of bioactive glass in alveolar process dimensions after exodontia. *Oral Surgery Oral Medicine Oral Pathology Oral Radiology Endodontics* **90**: 581–586.
- Cardaropoli, D., Tamagnone, L., Roffredo, A. & Gaviglio, L. (2014) Relationship between the buccal bone plate thickness and the healing of post extraction sockets with/without ridge preservation. *The International Journal of Periodontics and Restorative Dentistry* **34**: 211–217.
- Cook, D.C. & Mealey, B.L. (2013) Histologic comparison of healing following tooth extraction with ridge preservation using two different xenograft protocols. *Journal of Periodontology* **84**: 585–594.
- Coomes, A.M., Mealey, B.L., Huynh-Ba, G., Barboza-Arguello, C., Moore, W.S. & Cochran, D.L. (2014) Buccal bone formation after flapless extraction: a randomized, controlled clinical trial comparing recombinant human bone morphogenetic protein 2/absorbable collagen carrier and collagen sponge alone. *Journal of Periodontology* **85**: 525–535.
- Crespi, R., Cappare, P. & Gherlone, E. (2009) Magnesium-enriched hydroxyapatite compared to calcium sulfate in the healing of human extraction sockets: radiographic and histomorphometric evaluation at 3 months. *Journal of Periodontology* **80**: 210–218.
- Crespi, R., Cappare, P. & Gherlone, E. (2011a) Comparison of magnesium-enriched hydroxyapatite and porcine bone in human extraction socket healing: a histologic and histomorphometric evaluation. *The International Journal of Oral & Maxillofacial Implants* **26**: 1057–1062.
- Crespi, R., Cappare, P., Romanos, G.E., Mariani, E., Benasciutti, E. & Gherlone, E. (2011b) Cortico-cancellous porcine bone in the healing of human extraction sockets: combining Histomorphometry with osteoblast gene expression profiles *in vivo*. *The International Journal of Oral & Maxillofacial Implants* **26**: 866–872.
- Darby, I., Chen, S.T. & Buser, D. (2009) Ridge preservation techniques for implant therapy. *International Journal of Oral Maxillofacial Implants* **24**(Suppl): 260–271.
- De Risi, V., Clementini, M., Vittorini, G., Mannocci, A. & De Sanctis, M. (2013) Alveolar ridge preservation techniques: a systematic review and meta-analysis of histological and histomorphometric data. *Clinical Oral Implants Research*. 1–19.
- Eskow, A.J. & Mealey, B.L. (2014) Evaluation of healing following tooth extraction with ridge preservation using cortical versus cancellous freeze-dried bone allograft. *Journal of Periodontology* **85**: 514–524.
- Esposito, M., Cannizzaro, G. & Bozzoli, P. (2008) Efficacy of prophylactic antibiotics for dental implants: a multi centre placebo-controlled randomised clinical trial. *European Journal Oral Implantology* **1**: 23–31.
- Farmer, M. & Darby, I. (2014) Ridge dimensional changes following single-tooth extraction in the aesthetic zone. *Clinical Oral Implants Research* **25**: 272–277.
- Fernandes, P.G., Novaes, A.B., de Queiroz, A.C., de Souza, S.L.S., Taba, M., Palioto, D.B. & Grisi, M. F. (2011) Ridge preservation with acellular dermal matrix and anorganic bone matrix cell-binding peptide P-15 after tooth extraction in humans. *Journal of Periodontology* **82**: 72–79.
- Festa, V.M., Addabbo, F., Laino, L., Femiano, F. & Rullo, R. (2013) Porcine-derived xenograft combined with a soft cortical membrane versus extraction alone for implant site development: a clinical study in humans. *Clinical Implant Dentistry and Related Research* **15**: 707–713.
- Feuille, F., Knapp, C., Brunsvold, M. & Mellonig, J. (2003a) Clinical and histologic evaluation of bone-replacement grafts in the treatment of localized alveolar ridge defects. Part 1: mineralized freeze-dried bone allograft. *International Journal of Periodontics & Restorative Dentistry* **23**: 28–35.
- Feuille, F., Knapp, C.I., Brunsvold, M.A. & Mellonig, J.T. (2003b) Clinical and histologic evaluation of bone-replacement grafts in the treatment of localized alveolar ridge defects. Part 1: mineralized freeze-dried bone allograft. *International Journal Periodontics Restorative Dentistry* **23**: 29–35.
- Fiorellini, J.P., Howell, T.H., Cochran, D., Malmquist, J., Lilly, L.C., Spagnoli, D., Toljanic, J., Jones, A. & Nevins, M. (2005) Randomized study evaluating recombinant human bone morphogenetic protein-2 for extraction socket augmentation. *Journal of Periodontology* **76**: 605–613.
- Froum, S., Cho, S.-C., Rosenberg, E., Rohrer, M. & Tarnow, D. (2002) Histological comparison of healing extraction sockets implanted with bioactive glass or demineralized freeze-dried bone allograft: a pilot study. *Journal of Periodontology* **73**: 94–102.

- Garg, A.K. (2001) Preservation, augmentation, and reconstruction of the alveolar ridge. *Dental Implantology Update* **12**: 81–85.
- Gholami, G.A., Najafi, B., Mashhadiabbas, F., Goetz, W. & Najafi, S. (2012) Clinical, histologic and histomorphometric evaluation of socket preservation using a synthetic nanocrystalline hydroxyapatite in comparison with a bovine xenograft: a randomized clinical trial. *Clinical Oral Implants Research* **23**: 1198–1204.
- Gross, J. (1995) Ridge preservation using HTR synthetic bone following tooth extraction. *General Dentistry* **43**: 364–367.
- Higgins, J.P.T. & Green, S. (2011) *Cochrane Handbook for Systematic Reviews of Interventions*. Version 5.1.0 [updated March 2011]. Chichester: The Cochrane Collaboration, 2011. Available from www.cochrane-handbook.org (accessed 1 May 2015)
- Higgins, J.P., Thompson, S.G., Deeks, J.J. & Altman, D.G. (2003) Measuring inconsistency in meta-analyses. *British Medical Journal* **327**: 557–560.
- Hoang, T.N. & Mealey, B.L. (2012) Histologic comparison of healing after ridge preservation using human demineralized bone matrix putty with one versus two different-sized bone particles. *Journal of Periodontology* **83**: 174–181.
- Horvath, A., Mardas, N., Mezzomo, L.A., Needleman, I.G. & Donos, N. (2013) Alveolar ridge preservation. A systematic review. *Clinical Oral Investigations* **17**: 341–363.
- Hsun-Liang, C., Guo-Hao, L., Jia-Hui, F. & Hom-Lay, W. (2013) Alteration in bone quality after socket preservation with grafting materials: a systematic review. *The International Journal of Oral and Maxillo-Facial Implants* **28**: 710–720.
- Huh, J., Lee, H., Jang, J., Kim, M., Yun, P., Kim, S., Choi, K., Cho, K. & Shin, S. (2011) Randomised clinical trial on the efficacy of escherichia coli-derived rhbmp-2 with B-TCP/HA in extraction socket. *The Journal of Advanced Prosthodontics* **3**: 161–165.
- Iasella, J.M., Greenwell, H., Miller, R.L., Hill, M., Drisko, C., Bohra, A.A. & Scheetz, J.P. (2003) Ridge preservation with freeze-dried bone allograft and a collagen membrane compared to extraction alone for implant site development: a clinical and histologic study in humans. *Journal of Periodontology* **74**: 990–999.
- Johnson, K. (1969) A study of the dimensional changes occurring in the maxilla following tooth extraction. *Australian Dental Journal* **14**: 241–244.
- Jung, R.E., Fenner, N., Hammerle, C.H.F. & Zitzmann, N.U. (2013) Long-term outcome of implants placed with guided bone regeneration (GBR) using resorbable and non-resorbable membranes after 12–14 years. *Clinical Oral Implants Research* **24**: 1065–1073.
- Jung, R.E., Siegenthaler, D.W. & Hammerle, C.H. (2004) Post extraction tissue management: a soft tissue punch technique. *International Journal of Periodontics and Restorative Dentistry* **24**: 545–553.
- Karaca, Ç., Er, N., Gülşahi, A. & Köseoğlu, O. (2015) Alveolar ridge preservation with a free gingival graft in the anterior maxilla: volumetric evaluation in a randomized clinical trial. *International Journal Oral Maxillofacial Surgery* **44**: 774–780.
- Kim, Y., Lee, J., Kim, J., Park, J., Shin, S. & Choo, K. (2014) Ridge preservation using demineralized bone matrix gel with recombinant human bone morphogenic protein-2 after tooth extraction: a randomised controlled clinical trial. *Journal of Oral Maxillofacial Surgery* **77**: 1281–1291.
- Lekovic, V., Camargo, P.M., Klokkevold, P.R., Weinlaender, M., Kenney, E.B., Dimitrijevic, B. & Nedic, M. (1998) Preservation of alveolar bone in extraction sockets using bioabsorbable membranes. *Journal of Periodontology* **69**: 1044–1049.
- Lindhe, J., Cecchinato, D., Donati, M., Tomasi, C. & Liljenberg, B. (2014) Ridge preservation with the use of deproteinized bovine bone mineral. *Clinical Oral Implants Research* **25**: 786–790.
- Mardas, N., Chadha, V. & Donos, N. (2010) Alveolar ridge preservation with guided bone regeneration and a synthetic bone substitute or a bovine-derived xenograft: a randomized, controlled clinical trial. *Clinical Oral Implants Research* **21**: 688–698.
- Mardas, N., Trullenque-Eriksson, A., MacBeth, N., Petrie, A. & Donos, N. (2015) Does ridge preservation following tooth extraction improve implant treatment outcomes: a systematic review. *Clinical Oral Implant Research*. 1–12.
- Mardingier, O., Vered, M., Chaushu, G. & Nissan, J. (2012) Histomorphometrical analysis following augmentation of infected extraction sites exhibiting severe bone loss and primarily closed by intrasocket reactive soft tissue. *Clinical Implant Dentistry and Related Research* **14**: 359–365.
- Meloni, S.M., Tallarico, M., Lolli, F.M., Deledda, A., Pisano, M. & Jovanovic, S.A. (2015) Post extraction socket preservation using epithelial connective tissue graft vs porcine collagen matrix. 1-year results of a randomised controlled trial. *European Journal of Oral Implantology* **8**: 39–48.
- Morjaria, K.R., Wilson, R. & Palmer, R.M. (2014) Bone healing after tooth extraction with or without an intervention: a systematic review of randomized controlled trials. *Clinical Implant Dentistry and Related Research* **16**: 1–20.
- Neiva, R.F., Tsao, Y.-P., Eber, R., Shotwell, J., Billy, E. & Wang, H.-L. (2008) Effects of a putty-form hydroxyapatite matrix combined with the synthetic cell-binding peptide P-15 on alveolar ridge preservation. *Journal of Periodontology* **79**: 291–299.
- Pagni, G., Pellegrini, G., Giannobile, W. & Rasperini, G. (2012) Post extraction alveolar ridge preservation: biological basis and treatment. *International Journal of Dentistry* **2012**: 151030: 0–13.
- Perelman-Karmon, M., Kozlovsky, A., Liloy, R. & Artzi, Z. (2012) Socket site preservation using bovine bone mineral with and without a bio-resorbable collagen membrane. *The International Journal of Periodontics and Restorative Dentistry* **32**: 459–465.
- Pinho, M.N., Roriz, V.L.M., Novaes, A.B., Jr, Taba, M., Jr, Grisi, M.F.M., De Souza, S.L.S., et al. (2006) Titanium membranes in prevention of alveolar collapse after tooth extraction. *Implant Dentistry* **15**: 53–61.
- Poulias, E., Greenwell, H., Hill, M., Morton, D., Vidal, R., Shumway, B. & Peterson, T.L. (2013) Ridge preservation comparing socket allograft alone to socket allograft plus facial overlay xenograft: a clinical and histologic study in humans. *Journal of Periodontology* **84**: 1567–1575.
- Prato, G.P., Cairo, F., Tinti, C., Cortellini, P., Muzzi, L. & Mancini, E.A. (2004) Prevention of alveolar ridge deformities and reconstruction of lost anatomy: a review of surgical approaches. *International Journal Periodontics Restorative Dentistry* **24**: 434–445.
- Schropp, L., Isidor, F., Kostopoulos, L. & Wenzel, A. (2005) Interproximal papilla levels following early versus delayed placement of a single-tooth implants: a controlled clinical trial. *International Journal Oral Maxillofacial Implants* **20**: 753–761.
- Seibert, J.S. (1983) Reconstruction of deformed, partially edentulous ridges, using full thickness onlay grafts. Part I. technique and wound healing. Compendium continuing education. *Dentistry* **4**: 437–453.
- Serino, G., Biancu, S., Iezzi, G. & Piattelli, A. (2003) Ridge preservation following tooth extraction using a polylactide and polyglycolide sponge as space filler: a clinical and histological study in humans. *Clinical Oral Implants Research* **14**: 651–658.
- Studer, S.P., Lehner, C., Bucher, A. & Scharer, P. (2000) Soft tissue correction of a single-tooth pontic space: a comparative quantitative volume assessment. *Journal Prosthetic Dentistry* **83**: 402–411.
- Tan, W.L., Wong, T.L.T., Wong, M.C.M. & Lang, N.P. (2012) A systematic review of post-extraction alveolar hard and soft tissue dimensional changes in humans. *Clinical Oral Implants Research* **23**: 1–21.
- Tarnow, D., Eskow, R. & Zamzok, J. (1996) Aesthetic and implant dentistry. *Periodontology 2000* **11**: 85–94.
- Thoma, D.S., Benic, G.I., Zwahlen, M., Hammerle, C.H. & Jung, R.E. (2009) A systematic review assessing soft tissue augmentation techniques. *Clinical Oral Implants Research* **4**: 146–165.
- Vance, G.S., Greenwell, H., Miller, R.L., Hill, M., Johnston, H. & Scheetz, J.P. (2004) Comparison of an allograft in an experimental putty carrier and a bovine-derived xenograft used in ridge preservation: a clinical and histologic study in humans. *The International Journal of Oral & Maxillofacial Implants* **19**: 491–497.
- Vignoletti, F., Matesanz, P., Rodrigo, D., Figuero, E., Martin, C. & Sanz, M. (2012) Surgical protocols for ridge preservation after tooth extraction. A systematic review. *Clinical Oral Implants Research* **23**: 22–38.
- Vignoletti, F., Nunez, J. & Sanz, M. (2014) Soft tissue wound healing at teeth, dental implants and the edentulous ridge when using barrier membranes, growth and differentiation factors and soft tissue substitutes. *Journal of Clinical Periodontology* **41**: S23–S35.

- Wallace, S., Snyder, M. & Prasad, H. (2013) Post extraction ridge preservation and augmentation with mineralized allograft with or without recombinant human platelet-derived growth factor Bb (Rhpdgf-Bb): a consecutive case series. *The International Journal of Periodontics and Restorative Dentistry* **33**: 599–609.
- Wang, H., Kiyonobu, K. & Neiva, R. (2004) Socket augmentation: rationale and technique. *Implant Dentistry* **13**: 286–296.
- Wang, R.E. & Lang, N.P. (2012) Ridge preservation after tooth extraction. *Clinical Oral Implants Research* **23**: 147–156.
- Wood, R.A. & Mealey, B.L. (2012) Histologic comparison of healing after tooth extraction with ridge preservation using mineralized versus demineralized freeze-dried bone allograft. *Journal of Periodontology* **83**: 329–336.