

Clinical Report

Infliximab as long-term maintenance in steroid-resistant and recurrent sarcoidosis in a renal transplant with central nervous system involvement

Shalabh Srivastava¹, Ravindra Rajakariar¹, Neil Ashman¹, Martin Raftery¹, Heather Brown² and Joanne E. Martin¹

¹Renal Unit, The Royal London Hospital, London and ²Guys and St. Thomas's Hospital, London

Correspondence and offprint requests to: Shalabh Srivastava; E-mail: shalabhsrivastava@doctors.org.uk

Abstract

Sarcoidosis is a multisystemic, granulomatous disease of unknown aetiology, which commonly involves the lungs, skin and the eyes. Renal sarcoidosis is rare. Recurrent renal sarcoidosis leading to transplant graft failure in adults has not been reported. We report a single case of steroid-resistant sarcoid with recurrence in a renal transplant and the central nervous system that was managed with infliximab. We describe successful resolution of granulomas in the transplant kidney and stabilization of renal function with catastrophic central nervous system recurrence upon withdrawal of infliximab.

Case report

A 19-year-old man was diagnosed to have sarcoidosis after presenting with lethargy, weight loss, hypercalcaemia, splenomegaly and acute kidney injury (serum creatinine—400 mmol/L). He was started on prednisolone, which led to an improvement in his renal function with his serum creatinine falling to 160 mmol/L. He was maintained on 5 mg of prednisolone. He re-presented 1 year later with headache, blurred vision and hypercalcaemia. An MRI brain showed a 9 mm lesion in the frontal lobe, which was consistent with a granuloma. The dose of prednisolone was increased to 40 mg and azathioprine 150 mg was added. A repeat scan showed no enhancement of the frontal lobe lesion.

In search of other organ involvement, a high resolution CT of the lungs, lung function tests and cardiac MRI were done, all of which were normal. His renal function continued to deteriorate and a repeat renal biopsy showed a globally scarred kidney. He progressed to end-stage renal failure and was started on haemodialysis at the age of 21 years.

He received a heart-beating deceased donor kidney the same year and was given standard immunosuppression with cyclosporin, mycophenolate mofetil (MMF) and prednisolone with no induction. He had stable graft function (serum creatinine ~100 mmol/L) for 4 months when his serum creatinine climbed to 160 mmol/L. A transplant renal biopsy showed recurrence of sarcoidosis in his transplant kidney (Figure 1). The transplant biopsy was negative for C4d staining and no donor-specific antigens were detected in the patient's serum. There was no evidence of infectious causes of granulomatous disease. He was pulsed with methylprednisolone (500 mg) and the subsequent dose of prednisolone was increased to 20 mg. The serum creatinine fell to 139 mmol/L. Due to lack of further improvement in renal function, a biopsy was repeated 2 months later (Figure 2).

At this juncture, this 21-year-old man was on high-dose steroids and had ongoing active granulomatous tubulo-

interstitial nephritis (TIN) potentially rendering him untransplantable in the future. He was becoming increasingly Cushingoid with rising blood glucose levels.

We treated this patient with infliximab 5 mg/kg at 0, 2 and 6 weeks as induction and 8 weekly maintenance infusions. His cyclosporine was withdrawn with MMF and prednisolone (25 mg) ongoing. At Month 4 re-assessment, his prednisolone was at 15 mg with serum creatinine, 110 mmol/L. He had had four infliximab infusions completed without any adverse events. A repeat renal biopsy was performed (Figure 3). This showed marked reduction in the granulomatous TIN.

Infliximab was withdrawn after 10 infusions. His renal function was stable with a serum creatinine of 110 mmol/L. He re-presented after a few months with spastic paraparesis. An MRI brain and spinal cord showed multiple inflammatory lesions. His transplant function remained stable at this point. He was diagnosed with aggressive neurosarcoid. He was treated with pulsed steroids and infliximab was recommenced. He is currently on 8 weekly infusions of infliximab. His renal function continues to remain stable. He remains wheelchair bound from his paraparesis.

Discussion

Renal involvement in sarcoidosis is rare. Its recurrence after transplantation usually follows a mild clinical course and is responsive to increased immunosuppression. It has been reported recently that it is safe to perform renal transplantation in sarcoidosis with close clinical and histological monitoring [1]. Graft loss from sarcoidosis has not been reported in adults. There has been one case report of the use of infliximab in a paediatric renal transplant recipient with steroid resistant sarcoidosis [2].

There is good evidence on the pathologic role of TNF- α in sarcoidosis. The granulomas consist of a core of macrophages, epithelioid cells and multinucleated giant cells

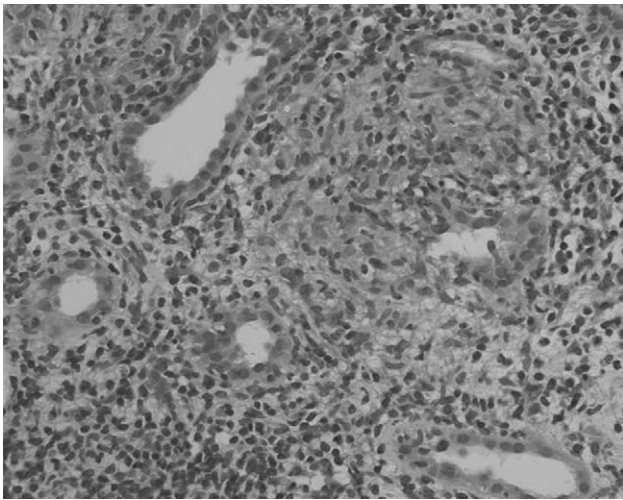


Fig. 1. Transplant renal biopsy: several areas of discrete parenchymal non-caseating granuloma. No evidence of rejection.

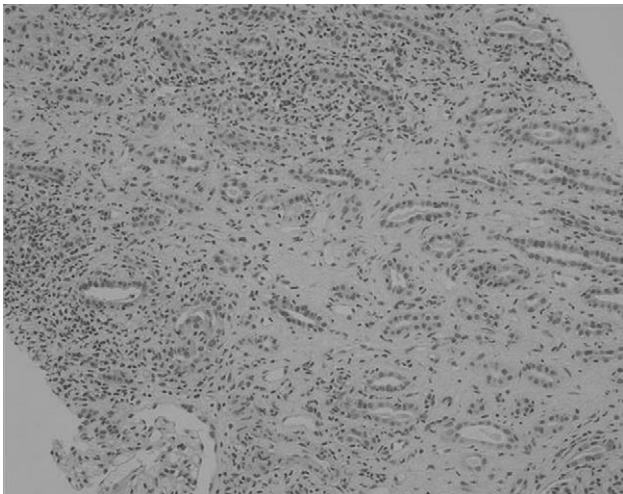


Fig. 2. Severe tubular atrophy and scarring with active granulomatous tubulointerstitial nephritis.

surrounded by monocytes, lymphocytes, fibroblasts and mast cells. $TNF-\alpha$ has a role to play in monocyte recruitment and cytokine-mediated T-lymphocyte activation and proliferation. It also promotes macrophage aggregation via up-regulation of Intercellular Adhesion Molecule-1 (ICAM-1).

Infliximab is a chimaeric monoclonal antibody, which binds free $TNF-\alpha$ and sometimes cell surface $TNF-\alpha$. Menon *et al.* [3] have reported the use of infliximab in interferon- α -associated renal sarcoid in a single case report. There has been one randomized controlled trial comparing placebo and infliximab in pulmonary sarcoid (Baughman *et al.* [4]). They randomized 138 patients with chronic pulmonary sarcoid to receive placebo or infliximab at 3 or 5 mg/kg body weight. In the infliximab groups, there was combined increase of 2.5% in FVC compared to no change in the placebo group ($P = 0.038$) at 24 weeks. There was no difference in the secondary end points for any of the other criteria. The data to support the use of infliximab in renal sarcoid is very poor and is limited to very few anecdotal case reports.

The long-term safety of biological agents has been studied in the patients undergoing treatment for autoim-

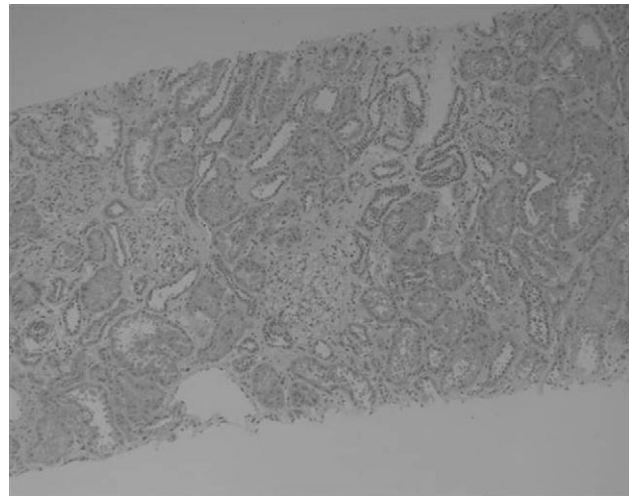


Fig. 3. Scarring presumed secondary to previous granulomatous tubulointerstitial nephritis, but no active inflammation on biopsy.

mune diseases like rheumatoid arthritis. In an overview assessing the safety of biological agents, Khraishi *et al.* [5] reported a significantly increased risk of reactivation of TB (54/100 000 treated) and opportunistic infections like aspergillosis, listeria, pneumocystis and herpes immediately after starting therapy [6]. There is increased risk of malignancy with immunosuppression as has been seen in renal transplantation [7].

In an overview of the US National Databank for Rheumatic Diseases, Wolfe *et al.* [8] have reported an increased risk of melanoma, odds ratio [OR 2.6 (95% confidence interval (CI) 1.0–6.7) $P = 0.056$] and non-melanotic skin cancer OR [1.7 (95% CI 1.3–2.2) $P < 0.001$] with the use of infliximab. There was no increased risk of any other malignancies.

In summary, we report successful resolution of sarcoid granulomas in a renal transplant with infliximab. Withdrawal of infliximab led to a catastrophic relapse in the brain and the spinal cord. There have been no adverse events related to the infusion or therapy. This case is encouraging as infliximab led to a resolution of renal sarcoid granulomas and stabilization of graft function.

Conflict of Interest Statement: None declared.

References

1. Aouizerate J *et al.* Renal transplantation in patients with sarcoidosis: a French multicenter study. *Clin J Am Soc Nephrol* 2010; 5: 2101–2108
2. Vargas F *et al.* Recurrence of granulomatous interstitial nephritis in transplanted kidney. *Pediatr Transplant* 2010; 14: e54–e57
3. Menon Y, Cucurull E, Reisin E *et al.* Interferon-alpha-associated sarcoidosis responsive to Infliximab therapy. *Am J Med Sci* 2004; 328: 173–175
4. Baughman RP, Drent M, Kavuru M *et al.* Sarcoidosis. Investigators. Infliximab therapy in patients with chronic sarcoidosis and pulmonary involvement. *Am J Respir Crit Care Med* 2006; 174: 795–802
5. Khraishi M. Comparative overview of safety of biologics in rheumatoid arthritis. *J Rheumatol* 2009; 36 (suppl.82): 25–32
6. Bongartz T, Sutton AJ, Sweeting MJ *et al.* Anti TNF antibody therapy in rheumatoid arthritis and the risk of serious infections and malignancies systematic review and meta analysis of rare

- harmful effects in randomized controlled trials. *JAMA* 2006; 295: 2275-2285
7. Kasiske BL, Snyder JJ, Gilbertson DT et al. Cancer after kidney transplantation in the United States. *Am J Transplant* 2004; 4: 905-913
 8. Wolfe F, Michaud K. Biologic treatment of rheumatoid arthritis and the risk of malignancy. *Arthritis Rheum* 2007; 56: 2886-2895

Received for publication: 13.6.11; Accepted in revised form: 6.9.11